



Contents lists available at ScienceDirect

Gynecology and Minimally Invasive Therapy

journal homepage: www.e-gmit.com

Case report

A three-step evaluation for safer curettage treatment of cesarean scar pregnancy

Tomomi Matsushita^{a,*}, Shin Takenaka^a, Makoto Nakabayashi^b, Koichi Ogawa^a, Akihiko Sekizawa^b^a Department of Obstetrics and Gynecology, Fujigaoka Hospital, Showa University School of Medicine, Kanagawa, Japan^b Department of Obstetrics and Gynecology, Showa University School of Medicine, Tokyo, Japan

ARTICLE INFO

Article history:

Received 27 May 2016

Received in revised form

18 January 2017

Accepted 6 February 2017

Available online 15 March 2017

Keywords:

cesarean scar pregnancy

cesarean section

endoscopy

pregnancy loss

ABSTRACT

Dilation and curettage is one of the treatment options for cesarean scar pregnancy, however, it sometimes requires a salvage therapy. Few reports discuss the methods of evaluating cesarean scar pregnancy before therapeutic procedures. We aimed to present a case study in which a three-step approach using a combination of preoperational sonohysterography, hysteroscopy, and laparoscopy was performed to evaluate cesarean scar pregnancy. A 33-year-old, G2P2, Japanese female with a history of two elective cesarean sections was diagnosed with viable cesarean scar pregnancy. We used the three-step approach right after undergoing bilateral uterine artery embolization and confirmed that there was a low possibility of fatal complications and we performed dilation and curettage. These steps could be done safely even if the cesarean scar pregnancy was viable. To perform safer curettage on cesarean scar pregnancy patients, these three steps seem to be useful.

Copyright © 2017, The Asia-Pacific Association for Gynecologic Endoscopy and Minimally Invasive Therapy. Published by Elsevier Taiwan LLC. This is an open access article under the CC BY-NC-ND license (<http://creativecommons.org/licenses/by-nc-nd/4.0/>).

Introduction

There is still no general consensus on the best treatment for cesarean scar pregnancy (CSP). Although dilation and curettage (D&C) is one of the options if patients hope to preserve the uterus, there are many reports that D&C in patients with CSP can require salvage therapy.^{1,2} Few reports discuss the methods of evaluating the risk of that happening. We describe a case study in which a three-step approach using a combination of preoperational sonohysterography, hysteroscopy, and laparoscopy was employed to evaluate CSP.

Case Report

The patient was a 33-year-old, G2P2, female who had a history of two elective cesarean sections. She first visited a private clinic

complaining of delayed menses; it had been approximately 6 weeks since her last menstrual period. She was diagnosed with an intra-uterine pregnancy via transvaginal ultrasonography. Six days later, she visited Fujigaoka Hospital (Kanagawa, Japan) due to severe lower abdominal pain and vaginal bleeding.

A blood test showed a high human chorionic gonadotrophin (hCG) level (118,530 mIU/mL). Transvaginal ultrasonography revealed a ring-shaped structure attached to the cesarean scar. It was 35 mm in diameter with a fetal heartbeat inside—it was therefore considered to be a gestational sac. The uterine wall above the sac was thin (2.5 mm; Figure 1A) and there was no continuity along the lateral sides. Color Doppler ultrasound showed blood flow through the anterior uterine wall. These images were consistent with CSP.

Magnetic resonance imaging was then performed to evaluate the site of pregnancy; however, no obvious image of the gestational sac was observed and we were unable to ascertain where the pregnant tissue was implanted.

D&C was considered to be the best choice of treatment. However, the pregnant tissue seemed to still be viable because the serum hCG level of 118,530 mIU/mL was high and cardiac activity was present at that time. Therefore, we performed several preoperative procedures to reduce the risk of treatment failure. First,

Conflicts of interest: The authors have no conflicts of interest relevant to this article.

* Corresponding author. Department of Obstetrics and Gynecology, Fujigaoka Hospital, Showa University School of Medicine, 1-30 Fujigaoka, Aobaku, Yokohama, 227-0043, Kanagawa, Japan.

E-mail address: t_posto@yahoo.co.jp (T. Matsushita).

<http://dx.doi.org/10.1016/j.gmit.2017.02.003>

2213-3070/Copyright © 2017, The Asia-Pacific Association for Gynecologic Endoscopy and Minimally Invasive Therapy. Published by Elsevier Taiwan LLC. This is an open access article under the CC BY-NC-ND license (<http://creativecommons.org/licenses/by-nc-nd/4.0/>).

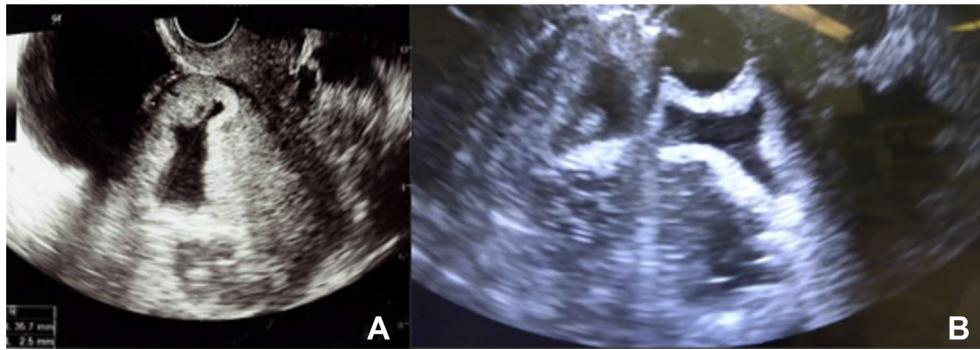


Figure 1. (A) Transvaginal ultrasonography on admission showing the thin anterior uterine myometrium (2.5 mm) and the gestational sac attached to the cesarean scar. (B) Sonohysterography showing the gestational sac floating in the water.

bilateral uterine artery embolization (UAE) was performed. We selectively embolized the bilateral uterine arteries using a spherical embolic material without any complications.

Next, within several hours after UAE, we performed sonohysterography as the first step and observed the inside wall of the uterus in the operation room (Figure 1B). As water was injected, we could observe the gestational sac floating in the water. This revealed that the area of the gestational sac that was attached to the uterine wall was actually smaller than that identified via ultrasonography. After sonohysterography, we used cervical dilators up to 8.8 mm in diameter under transabdominal ultrasound guidance, which led to a little bleeding. For the second step, we performed hysteroscopy to evaluate the myometrium invasion, which showed the gestational sac bulging from the anterior uterine wall (Figure 2A). No sign of invasion was seen in that area. For the third step, we performed laparoscopy while simultaneously performing hysteroscopy (Figure 2B and C). We confirmed that there was no bulging on the vesicouterine pouch and we could not see the light from the hysteroscope there with the

laparoscopic light off. There was no sign of uterine rupture or thinning of the myometrium.

Through these three steps, we ascertained that there was a low possibility of fatal complications and we finally performed D&C monitored by transabdominal ultrasound. We also prepared for an unexpected uterine rupture via laparoscopy during D&C so that we would suture the ruptured myometrium.

The surgery was successfully performed with minimal blood loss. All of the pregnant tissue, including the gestational sac, villi, and decidua were removed. The patient was discharged 3 days after the surgery. After 1 week, her serum hCG level was 1226 mIU/mL.

Discussion

We learned two clinically important lessons through this case: (1) the “three-step evaluation” method using sonohysterography, hysteroscopy, and laparoscopy was effective for confirming the precise localization of the pregnant tissue; and (2) this evaluation could be performed safely in a patient with viable CSP.

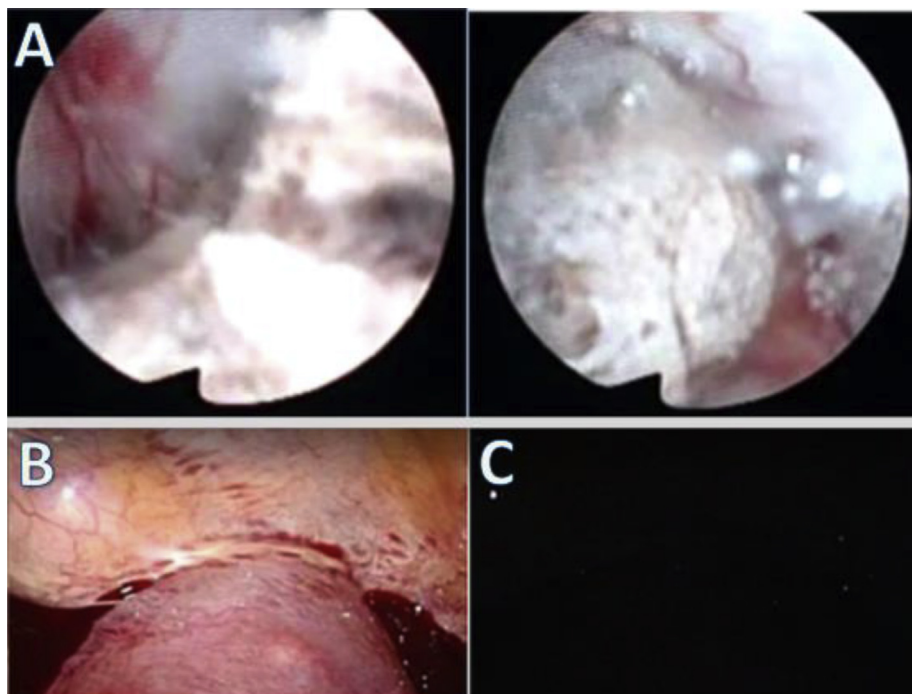


Figure 2. (A) Hysteroscopy showing a gap between the wall and the attached part of the gestational sac. (B) Laparoscopy with a light. No bulging was seen on the vesicouterine pouch. (C) Intra-abdominal space the light turned off. The light from the hysteroscope was not observed.

The three-step evaluation that was performed in the present study is effective for examining the site of implantation in CSP patients. There is no consensus on CSP treatment. Although curettage is less invasive, there is a report that indicates that it is associated with a high failure rate (76.1%) when it is used as the first treatment.² Even with a combination of UAE, unfavorable condition of the implantation site can lead to severe bleeding.³ We should be aware of the possibility of the invasion of villi, which is unreachable, into the myometrium around the cesarean scar (intramuscular type).^{4,5} This could potentially induce fatal blood loss from the persisted trophoblastic tissue. An accurate evaluation of the area around the cesarean scar is therefore important to decide whether curettage is possible before the procedure is performed. In the present case, we combined the three steps of sonohysterography, hysteroscopy, and laparoscopy to evaluate the cesarean scar and successfully performed curettage.

In viable cases, the safety of CSP can also be evaluated using this “three-step evaluation”. It has been reported that D&C can be performed when the mass is ≤ 4 cm in diameter without profuse peritrophoblastic flow, with an hCG level of ≤ 2000 mIU/L, and when the diminished myometrial layer between the bladder and the sac is >4 mm.⁶ However, these criteria are often not fulfilled in viable CSP cases. In this case, the myometrial layer was 2.5 mm and the patient’s serum hCG level was 110,000 mIU/m. Requiring further treatment after D&C due to the deep-embedded villi was still our major concern. The “three-step evaluation” allowed for the precise localization of this pregnancy and helped us to select D&C from among the treatment options for viable CSP.

We found few reports that mentioned the use of sonohysterography as a diagnostic tool. Tower and Frishman⁷ published a report entitled, “Cesarean Scar Defect and Gynecologic Complications,” which states the usefulness of saline infusion sonohysterography in the diagnosis of cesarean scar defect. Although all of the cases in the report were nonpregnant women, the method can be applied to CSP. In the present case, we injected water transvaginally. This helped us to detect the area in which the gestational sac was attached to the scar.

There are also few reports regarding evaluations using hysteroscopy. Saito et al.⁸ reported that the hysteroscopic approach is relevant for examining the implantation area, the bleeding point, and the amount of bleeding. Yang et al.⁹ reported that hysteroscopic surgery was advantageous for recognizing the distribution of the blood supply at the site of implantation. We considered that hysteroscopy is a useful tool for evaluating the site of implantation in order to allow us to decide the best treatment strategy. Sonohysterography and hysteroscopy are relatively easy to perform and involve minimal cost, time, and stress on patients.

In this case, we performed laparoscopy to evaluate the intra-abdominal cavity and the scar. We followed the report that described using the light source of the laparoscope to detect thinning of the uterine wall and checked to see whether light could be seen through the vesicouterine pouch.¹⁰ We also believe curettage with a laparoscope as a stand-by has an advantage in that it allows for management in the event of a uterine rupture especially in such cases with a viable CSP. Laparoscopy is a more invasive procedure, therefore, only sonohysterography and hysteroscopy might be sufficient for cases that seem to have a low possibility of a uterine rupture.

In conclusion, the three steps of sonohysterography, hysteroscopy, and laparoscopy, were useful for evaluating and minimizing the risks related to treatment of CSP in the present case. It could also be applied to viable CSP. Sonohysterography and hysteroscopy are relatively easy and less invasive procedures, thus these two methods are reasonable for determining the next step of treatment. Laparoscopy is technically demanding in comparison to the other two procedures. However, it is beneficial as it can be used for both examination and treatment. Further reports are needed to determine whether this three-step approach can be applied to other CSP cases.

References

1. Arslan M, Pata O, Dilek TU, Aktas A, Aban M, Dilek S. Treatment of viable cesarean scar ectopic pregnancy with suction curettage. *Int J Gynaecol Obstet*. 2005;89(2):163–166.
2. Rotas MA, Haberman S, Levigur M. Cesarean scar ectopic pregnancies: etiology, diagnosis, and management. *Obstet Gynecol*. 2006;107(6):1373–1381.
3. Sugawara J, Senoo M, Chisaka H, Yaegashi N, Okamura K. Successful conservative treatment of a cesarean scar pregnancy with uterine artery embolization. *Tohoku J Exp Med*. 2005;206(3):261–265.
4. Vial Y, Petignat P, Hohlfield P. Pregnancy in a cesarean scar. *Ultrasound Obstet Gynecol*. 2000;16(6):592–593.
5. Fylstra DL. Hysteroscopy and suction evacuation of cesarean scar pregnancies: a case report and review. *J Obstet Gynaecol Res*. 2014;40(3):853–857.
6. Zhang Y, Gu Y, Wang JM, Li Y. Analysis of cases with cesarean scar pregnancy. *J Obstet Gynaecol Res*. 2013;39(1):195–202.
7. Tower AM, Frishman GN. Cesarean scar defects: an underrecognized cause of abnormal uterine bleeding and other gynecologic complications. *J Minim Invasive Gynecol*. 2013;20(5):562–572.
8. Saito S, Tanabe K, Sato A, Akaishi M, Hayashi C. Live birth after a cesarean scar pregnancy treated with methotrexate administration, uterine artery embolization, hysteroscopic removal of conceptus, and laparoscopic repair of uterine scar: case report. *Jpn J Gynecol Obstetr Endoscopy*. 2014;30(1):101–105.
9. Yang Q, Piao S, Wang G, Wang Y, Liu C. Hysteroscopic surgery of ectopic pregnancy in the cesarean section scar. *J Minim Invasive Gynecol*. 2009;16(4):432–436.
10. Shigeta S, Ugajin T, Yuki H, Yaegashi N. Laparoscopic repair of uterine scar dehiscence after previous cesarean scar pregnancy: a case report. *Jpn J Gynecol Obstetr Endoscopy*. 2012;28(1):353–357.