

## Case Report

# Successful Procedure in Conservative Management of Interstitial (Cornual) Ectopic Pregnancy

Cepi Teguh Pramayadi\*, Alvin Bramantyo, Eka Rusdianto Gunardi

Department of Obstetrics and Gynecology, Division of Reproductive Health, Faculty of Medicine, Dr. Cipto Mangunkusumo National General Hospital, University of Indonesia, Jakarta, Indonesia

## Abstract

A 35-year-old woman presented with spotting and lower abdominal pain. Follow-up sonography was suggestive of interstitial ectopic pregnancy. Laparoscopic cornuostomy was carried out. Before incision, diluted vasopressin was injected around the site of interstitial pregnancy. Removal of the conceptual tissues was conducted smoothly through a 1.5 cm incision. The overall blood loss was 50 mL. The operative time was 50 min, and there were no intraoperative complications. We successfully performed laparoscopic cornuostomy, which was followed by an unremarkable postoperative course. Laparoscopic surgery is a safe and effective minimally invasive surgical intervention for interstitial ectopic pregnancy if performed by the experienced surgeon. Local vasopressin injection is a good alternative for bleeding control in conservative laparoscopic surgery.

**Keywords:** Ectopic pregnancy, interstitial pregnancy, laparoscopy, vasopressin

## INTRODUCTION

Interstitial (cornual) pregnancy is a rare type of ectopic pregnancy, accounting for 2%–4% of all tubal pregnancies, but with high maternal mortality of 2%–2.5%.<sup>[1]</sup> Interstitial pregnancy refers to an ectopic pregnancy that is implanted in the tubal segment traversing the muscular wall of the uterus. This section of tube is relatively thick, and it is located in highly vascular region. Therefore, interstitial ectopic pregnancy tends to rupture later, with more severe bleeding than those of other ectopic pregnancies.<sup>[2]</sup> Predisposing factors to interstitial pregnancy include history of previous ectopic pregnancy, ipsilateral salpingectomy, and *in vitro* fertilization.<sup>[1]</sup> Transvaginal ultrasound scan is imperative for the early diagnosis of interstitial pregnancy. A previous study outlined three sonographic criteria for diagnosis: (1) an empty uterine cavity, (2) a chorionic sac seen separately and at least 1 cm from the lateral edge of uterine cavity, and (3) a

thin (<5 mm) myometrial layer surrounding the gestational sac.<sup>[3]</sup> In the past, interstitial pregnancy was commonly treated by hysterectomy or cornual resection by laparotomy.<sup>[2]</sup> Recently, more conservative laparoscopic approaches have been developed, including cornual resection, cornuostomy, salpingostomy, and salpingectomy.<sup>[1]</sup> Aside from surgical treatment, interstitial pregnancy can also be managed medically using systemic or local injection of methotrexate.<sup>[2]</sup> Here, we present a case report of a 35-year-old woman with interstitial pregnancy who underwent a successful conservative laparoscopic cornuostomy.

## CASE REPORT

A 35-year-old woman, gravida 2, para 1, presented to the outpatient clinic with spotting and lower abdominal pain. She

**Address for correspondence:** Dr. Cepi Teguh Pramayadi,  
Department of Obstetrics and Gynecology, Division of Reproductive Health,  
Faculty of Medicine, Dr. Cipto Mangunkusumo National General Hospital,  
University of Indonesia, Salemba Raya Street, Number 6, Central Jakarta,  
Indonesia.  
E-mail: [cteguh@yahoo.com](mailto:cteguh@yahoo.com)

### Article History:

Received 28 February 2018  
Received in revised form 8 June 2018  
Accepted 29 June 2018  
Available online 26 September 2018

### Access this article online

#### Quick Response Code:



Website:  
[www.e-gmit.com](http://www.e-gmit.com)

DOI:  
10.4103/GMIT.GMIT\_9\_18

This is an open access journal, and articles are distributed under the terms of the Creative Commons Attribution-NonCommercial-ShareAlike 4.0 License, which allows others to remix, tweak, and build upon the work non-commercially, as long as appropriate credit is given and the new creations are licensed under the identical terms.

**For reprints contact:** [reprints@medknow.com](mailto:reprints@medknow.com)

**How to cite this article:** Pramayadi CT, Bramantyo A, Gunardi ER. Successful procedure in conservative management of interstitial (cornual) ectopic pregnancy. *Gynecol Minim Invasive Ther* 2018;7:172-4.

reported a previous history of primary infertility for 5 years, which was successfully managed by medical treatment, leading to an uncomplicated pregnancy and a cesarean section at term. She had no risk factor for ectopic pregnancy. On admission to the hospital, her vital signs were in normal range. Her abdominal and pelvic examinations were normal. Transvaginal ultrasound revealed empty uterus and a visible gestational sac located in the right cornu, 3.5 cm in size, surrounded by a layer of myometrium. Both the tubes and ovaries appeared normal. Laparoscopy was carried out 1 day following admission. An image suggestive of unruptured interstitial ectopic pregnancy, measuring approximately 3.5 cm, was observed during laparoscopy.

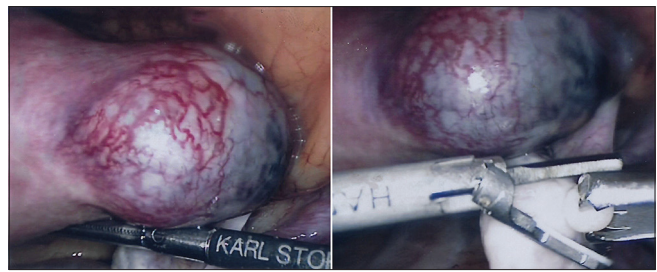
Laparoscopic cornuostomy was then performed. A 1.5 cm linear incision was made in the long axis of the interstitial pregnancy. Using blunt probe, the conceptual tissue were evacuated through the incision.

Before incision, a volume of 20 ml of diluted vasopressin solution (20 U in 100 mL normal saline) was injected into the surrounding myometrial tissue using a 20 gauge spinal needle.

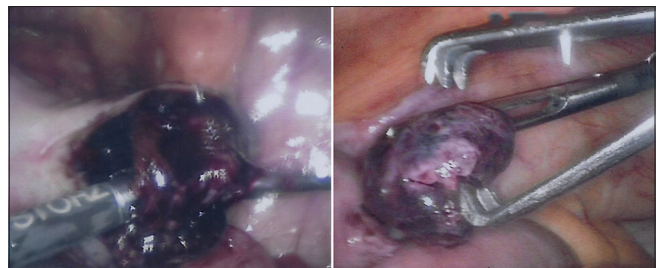
Complete blanching of the interstitial pregnancy was achieved. The uterine incision was carefully closed with interrupted myometrial suture technique using absorbable suture material. At the end of the procedure, the peritoneal cavity was carefully lavaged, and hemostasis confirmed. The operating time was 50 min and estimated blood loss was 50 ml. Histology of the specimen confirmed an ectopic pregnancy. The postoperative course was unremarkable, and the patient was discharged 48 h after the procedure [Figures 1-3].

## DISCUSSION

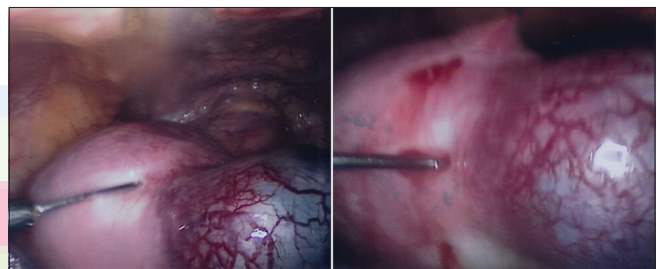
Early diagnosis is an important step in the management of interstitial pregnancy. Routine use of transvaginal ultrasonography and  $\beta$ -hCG level measurement, in addition to clinical examination, constitutes the principal diagnostic tools. Advances in these diagnostic tools have promoted detection of interstitial pregnancy before rupture, which has enabled the use of more conservative treatment options.<sup>[2,4]</sup> Laparoscopy offers some advantages over laparotomy, making it the preferred approach for interstitial pregnancy in hemodynamically stable patient. Laparoscopic treatment allows for a shorter hospital stay, faster recovery, and lower health-care cost.<sup>[5]</sup> Rupture of interstitial pregnancy may result in massive intra-abdominal bleeding and laparotomy could be considered in hemodynamically unstable patient with sign and symptoms of hypovolemic shock. However, massive hemoperitoneum is not a contraindication for laparoscopic management of interstitial pregnancy.<sup>[6]</sup> Laparoscopic approach should only be performed by a highly-skilled laparoscopic



**Figure 1:** Right interstitial ectopic pregnancy



**Figure 2:** Evacuation of conceptual tissues



**Figure 3:** Injection vasopressin around the cornual mass

surgeon that has the capabilities to convert to laparotomy quickly.<sup>[7]</sup> A series of 53 cases of cornual ectopic pregnancy described successful treatment using laparoscopic techniques in all cases, with no major intraoperative complication.<sup>[8]</sup> More conservative approaches, such as cornuostomy, were supposed to cause less anatomical damage compared to cornual resection.<sup>[9]</sup> In cornuostomy, the pregnancy is removed without removing the surrounding myometrium. To date, there is no consensus regarding the best surgical technique for interstitial pregnancy. A recently published article comparing cornual resection and cornuostomy in 75 interstitial pregnancy patients found comparable clinical result between the two techniques, with shorter operation time for cornuostomy.<sup>[10]</sup> This was in accordance with previous study describing 13 interstitial pregnancy cases, all of which were successfully treated with a laparoscopic colostomy, without any major complications. They suggest that laparoscopic cornuostomy is applicable for interstitial pregnancy at up to 10 weeks of gestation with a gestational mass of 50 mm or less.<sup>[11]</sup> The cornuostomy procedure usually includes injection of diluted vasopressin into the myometrium.<sup>[2]</sup> Vasopressin has been widely used for bleeding control in conservative laparoscopic surgeries

due to its potent vasoconstrictor effect.<sup>[12]</sup> However, local injection of vasopressin may lead to cardiovascular adverse effects if systemic injection occurs. Severe hypertension, myocardial infarction, and acute pulmonary edema have been reported after vasopressin use during surgical procedures.<sup>[13]</sup> Sufficient evidence on optimal concentration of vasopressin in relation to bleeding and safety in laparoscopic surgery is lacking.<sup>[12]</sup> Conservative surgical management has the potential of persistent ectopic pregnancy (PEP) after the procedure. The higher daily increase of preoperative  $\beta$ -hCG level (>40%) was found to be a risk factor for PEP after salpingotomy.<sup>[14]</sup> The scar of a previous interstitial ectopic pregnancy, akin to any other surgery to the uterus, may become a uterine rupture site in future pregnancy. Therefore, despite the fact that a successful delivery of an intrauterine term pregnancy after cornual resection has been reported,<sup>[15]</sup> cesarean section should be considered in laboring patient who had a history of these surgeries.

## CONCLUSION

Interstitial (cornual) ectopic pregnancy is a very rare condition. However, we managed to found it in our center. Here, we report a successful treatment of interstitial pregnancy by laparoscopic cornuostomy. It is a safe and effective minimally invasive surgical intervention if performed by an experienced surgeon. Local vasopressin injection is an appropriate method for bleeding control in conservative interstitial pregnancy treatment by laparoscopic surgery.

## Declaration of patient consent

The authors certify that they have obtained all appropriate patient consent forms. In the form the patient(s) has/have given his/her/their consent for his/her/their images and other clinical information to be reported in the journal. The patients understand that their names and initials will not be published and due efforts will be made to conceal their identity, but anonymity cannot be guaranteed.

## Financial support and sponsorship

Nil.

## Conflicts of interest

There are no conflicts of interest.

## REFERENCES

1. Tulandi T, Al-Jaroudi D. Interstitial pregnancy: Results generated from the society of reproductive surgeons registry. *Obstet Gynecol* 2004;103:47-50.
2. Moawad NS, Mahajan ST, Moniz MH, Taylor SE, Hurd WW. Current diagnosis and treatment of interstitial pregnancy. *Am J Obstet Gynecol* 2010;202:15-29.
3. Timor-Tritsch IE, Monteagudo A, Matera C, Veit CR. Sonographic evolution of cornual pregnancies treated without surgery. *Obstet Gynecol* 1992;79:1044-9.
4. Grindler NM, Ng J, Tocce K, Alvero R. Considerations for management of interstitial ectopic pregnancies: Two case reports. *J Med Case Rep* 2016;10:106.
5. Baumann R, Magos AL, Turnbull A. Prospective comparison of videopelviscopy with laparotomy for ectopic pregnancy. *Br J Obstet Gynaecol* 1991;98:765-71.
6. Chaudhary P, Manchanda R, Patil VN. Retrospective study on laparoscopic management of ectopic pregnancy. *J Obstet Gynaecol India* 2013;63:173-6.
7. Grobman WA, Milad MP. Conservative laparoscopic management of a large cornual ectopic pregnancy. *Hum Reprod* 1998;13:2002-4.
8. Ng S, Hamontri S, Chua I, Chern B, Siow A. Laparoscopic management of 53 cases of cornual ectopic pregnancy. *Fertil Steril* 2009;92:448-52.
9. MacRae R, Olowu O, Rizzuto MI, Odejinmi F. Diagnosis and laparoscopic management of 11 consecutive cases of cornual ectopic pregnancy. *Arch Gynecol Obstet* 2009;280:59-64.
10. Lee MH, Im SY, Kim MK, Shin SY, Park WI. Comparison of laparoscopic cornual resection and cornuotomy for interstitial pregnancy. *J Minim Invasive Gynecol* 2017;24:397-401.
11. Watanabe T, Watanabe Z, Watanabe T, Fujimoto K, Sasaki E. Laparoscopic cornuotomy for interstitial pregnancy and postoperative course. *J Obstet Gynaecol Res* 2014;40:1983-8.
12. Moon HS, Kim SG, Park GS, Choi JK, Koo JS, Joo BS, *et al.* Efficacy of bleeding control using a large amount of highly diluted vasopressin in laparoscopic treatment for interstitial pregnancy. *Am J Obstet Gynecol* 2010;203:30.e1-6.
13. Potter T, Fletcher H, Reid M. Vasopressin as a hemostatic and dissection aid at vaginal hysterectomy. *Int J Gynaecol Obstet* 2004;86:65-6.
14. Kemmann E, Trout S, Garcia A. Can we predict patients at risk for persistent ectopic pregnancy after laparoscopic salpingotomy? *J Am Assoc Gynecol Laparosc* 1994;1:122-6.
15. Andersen BB. Successful intrauterine term pregnancy after resection of cornual pregnancy. *Eur J Obstet Gynecol Reprod Biol* 1999;84:99-100.