

Case Report

Hysteroscopic Management of Retained Products of Conception

Yu-Hui Lin¹, Yung-Yi Cheng¹, Dah-Ching Ding^{2,3}

¹School of Medicine, Tzu Chi University, ²Department of Obstetrics and Gynecology, Hualien Tzu Chi Hospital, Buddhist Tzu Chi Foundation, Tzu Chi University,

³Institute of Medical Sciences, Tzu Chi University, Hualien, Taiwan

Abstract

We report a case with retained products of conception (RPOC) managed by hysteroscopic resection. A 45-year-old woman, G5P3SA1AA1, experienced spontaneous abortion on March 8, 2017, and had persistent vaginal bleeding since then. On May 12, 2017, she came to emergency room where endometrium biopsy was done and revealed degenerative gestational tissue with acute inflammation. On May 23, 2017, she followed up at outpatient department where ultrasonography showed no obvious intrauterine abnormalities with endometrial thickness of 6.5 mm. Office hysteroscopy was arranged and RPOC at the posterior uterine wall was suspected. She received hysteroscopic transcervical resection (TCR) of RPOC on May 26, 2017. After TCR, the vaginal bleeding discontinued. The pathology showed degenerative gestational products with acute inflammation. In conclusion, hysteroscopic TCR might be safe and feasible for RPOC.

Keywords: Hysteroscopy, product of conception, retained, resection

INTRODUCTION

Retained product of conception (RPOC) after miscarriage is common, but challenging problem. The RPOC has neither diagnostic criteria and treatments protocols nor guidelines. RPOC may cause persistent vaginal bleeding after miscarriage, infection, and long-term complications, such as intrauterine adhesions (IUA), even infertility. It needs accurate diagnosis, timely removal of RPOC, and least treatment-related complications.

We presented a case of RPOC managed by hysteroscopic transcervical resection (TCR) successfully.

CASE REPORT

A 45-year-old woman, G5P3SA1AA1, all children were born by normal spontaneous delivery. She went to our hospital on May 12, 2017, because of intermittent abdominal pain for 3 or 4 days. The last menstrual period was on January 9, 2017. Murphy sign was positive. Abdominal ultrasound showed gallstone and gallbladder dilatation. Acute cholecystitis was suspected. Abdomen to pelvis computed tomography showed gallbladder stone impacted in the neck and 1.9 cm enhanced nodule in the uterine cavity [Figure 1a and b]. She was admitted to general surgery for laparoscopic cholecystectomy and discharged on May 16, 2017.

The patient had experienced spontaneous abortion on March 18, 2017, (2 months before this admission) and persisted vaginal bleeding since then. We were consulted on May 12, 2017. On pelvic examination, vaginal bleeding was noted. Examination with transvaginal ultrasound revealed that the uterus was found 6.28 cm × 5.01 cm in size with the endometrium 6.5 mm in thickness [Figure 1c]. Incomplete abortion was suspected. Endometrium biopsy was done.

The patient visited our clinics on May 23, 2017. Pathological report showed degenerative gestational tissue with acute inflammation of the endometrium. A little vaginal bleeding was found on pelvic examination. Transvaginal sonography still showed no obvious intrauterine abnormalities. Hysteroscopy arranged at outpatient department (OPD) showed RPOC at the posterior uterine wall [Figure 2]. RPOC was diagnosed and hysteroscopic TCR was performed on May 26, 2017.

With posterior uterine endometrium bleeding and resected using resectoscopy [Figure 3], we resected the RPOC till no

Address for correspondence: Dr. Dah-Ching Ding,
Department of Obstetrics and Gynecology, Hualien Tzu
Chi Hospital, Buddhist Tzu Chi Medical Foundation,
No. 707, Sec. 3, Chung-Yang Rd., Hualien, Taiwan.
E-mail: dah1003@yahoo.com.tw

Access this article online

Quick Response Code:



Website:
www.e-gmit.com

DOI:
10.4103/GMIT.GMIT_27_18

This is an open access journal, and articles are distributed under the terms of the Creative Commons Attribution-NonCommercial-ShareAlike 4.0 License, which allows others to remix, tweak, and build upon the work non-commercially, as long as appropriate credit is given and the new creations are licensed under the identical terms.

For reprints contact: reprints@medknow.com

How to cite this article: Lin YH, Cheng YY, Ding DC. Hysteroscopic management of retained products of conception. *Gynecol Minim Invasive Ther* 2018;7:133-5.

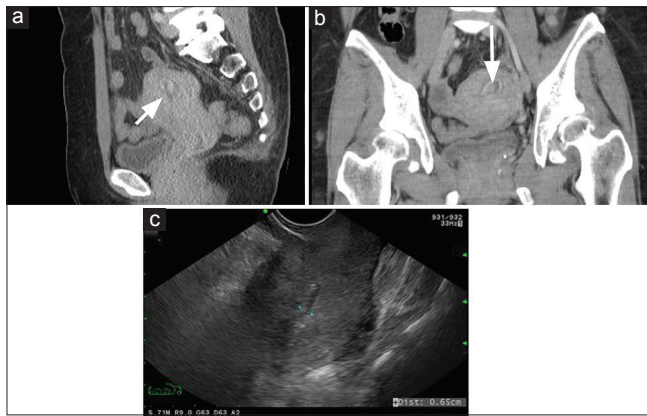


Figure 1: Image study of uterus. Abdominal to pelvis computed tomography on May 12, 2017 showed a 1.9 cm nodule with enhanced wall in uterine cavity. (a) Sagittal section; (b) coronal section. (c) Ultrasound of uterine endometrium

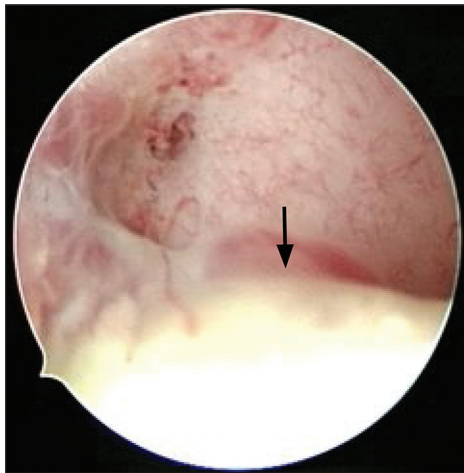


Figure 2: Outpatient department hysteroscopy was done on May 23, 2017 showing retained products of conception at posterior uterine wall (arrow)

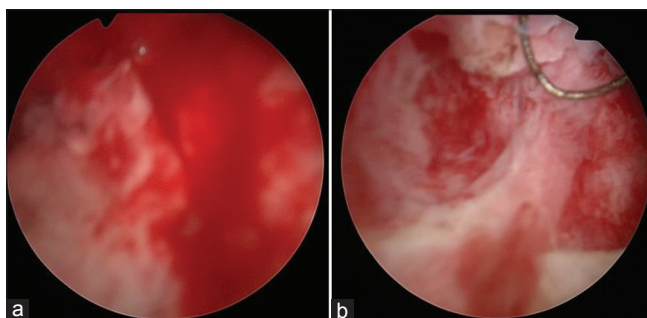


Figure 3: Posterior uterine wall of retained products of conception before (a) and after (b) transcervical resection

bleeding spot was noted. The patient was discharged after the surgery was finished, and OPD follow-up was arranged on June 2, 2017. At OPD, pathologic report revealed retained gestational products. Laboratory data showed beta-HCG less than 2.0 mIU/ml. One and three months after TCR visits, normal uterus and normal menstruation were noted.

DISCUSSION

Detecting RPOC with transvaginal ultrasound is a noninvasive assessment tool before medical or surgical treatments.^[1] Several kinds of sonographic features of RPOC were reported, such as endometrial mass, greater endometrial thickness (ET), and high endometrial vascularity.

Endometrial mass is the most sensitive (79%) and specific (89%) feature for RPOC.^[2] Color Doppler flow is more often detected in the endometrium when RPOC are present (75%) than in the absence of RPOC (40%).^[2]

Image of RPOC on hysteroscopy looked like whitish materials with some villi-like picture attached the uterine wall.^[3,4] Using hysteroscopy, RPOC can easily be differentiated with surrounding normal endometrium.^[3,4] In our case, RPOC also presented as whitish materials along the endometrium, can be differentiated with the normal endometrium.

Esmaeillou *et al.* compared the diagnostic performance of $ET \geq 10$ mm, vascular pattern, and endometrial echogenic mass;^[1] they found that combination of endometrial vascularity and hyperechoic mass is the best predictor of RPOC, with 88% sensitivity, 89% specificity, 85% positive predictive value, and 93% negative predictive value. They also found that $ET \geq 10$ mm is a doubtful parameter in detecting RPOC, because 52% patients with $ET \geq 10$ mm had no RPOC, in other words a high false-positive rate. In this concern, Zare and Zijerdi suggested an ET of 11.25 mm or more as the cutoff point while using ET alone, with the sensitivity of 81%, specificity of 45%, and area under curve of 0.7.^[5]

Avoiding unnecessary surgery may be reasonable if the sonographic features do not meet the cutoff values. In the present investigation, examination with transvaginal ultrasound revealed the endometrium 6.5 mm in thickness, well under 11.25 mm cutoff point. Hysteroscopy was performed due to still highly suspicion of RPOC, and a lesion was identified at the posterior wall of uterus and was pathologically confirmed the degenerative production of conception with acute inflammation.

Dilatation and curettage (D and C) is the most often treatment for RPOC. Hysteroscopic resection, however, has been improved in terms of low intrauterine adhesion rates, favorable reproductive outcomes, and visualizing condition of the uterus directly. Hysteroscopic removal of RPOC is direct visualization of uterine cavity so that the removal caused minimal trauma to endometrium.

Theoretically, higher complication rates of infection and uterine perforation might be seen in hysteroscopy because the postpartum condition of the uterus may predispose to the complications. Several studies had proved low surgical complication rates and favorable long-term outcomes. A meta-analysis including five studies and 326 patients who underwent the hysteroscopic removal of RPOC revealed a complication as low as 0.3%, which contained 1/326 patients

of uterine perforation and 1/326 patients of systemic infection only.^[6]

The long-term complications such as intrauterine complication and infertility were described more detailed by Hooker *et al.*,^[7] the first systematic review reporting the IUAs and reproductive outcomes after the management of RPOC. IUAs were reported 29.4% in the D and C group and 12.8% in the hysteroscopic resection group, respectively. The D and C group also had significantly more IUA ($P < 0.01$). In reproductive outcome, hysteroscopic resection group had an earlier conception tendency than D and C group. From the above findings, Hooker *et al.* suggested that IUAs and infertility should be considered when women suspected of RPOC are managed.

In our case, though there was not any ultrasonographic feature supporting the suspicion of RPOC, TCR of the RPOC at the posterior wall was done smoothly. The problem of scanty vaginal bleeding was resolved. Moreover, there were neither surgical complications such as infection, uterine perforation, or intravasation of hysteroscopic distension media, nor fluid overload.

CONCLUSION

Hysteroscopic resection of RPOC is safe and feasible. Previous literature had shown hysteroscopy is superior to traditional curettage, with low complication, low rates of IUA, and higher rates of subsequent pregnancy.

Declaration of patient consent

The authors certify that they have obtained all appropriate patient consent forms. In the form the patient(s) has/have given his/her/their consent for his/her/their images and other clinical information to be reported in the journal. The patients understand that their names and initials will not be published

and due efforts will be made to conceal their identity, but anonymity cannot be guaranteed.

Acknowledgment

We thank Dr. Jon-Son Kuo for English editing.

Financial support and sponsorship

Nil.

Conflicts of interest

There are no conflicts of interest.

REFERENCES

1. Esmacillou H, Jamal A, Eslamian L, Marsousi V, Sarvi F, Kokab A. Accurate detection of retained products of conception after first- and second-trimester abortion by color Doppler sonography. *J Med Ultrasound* 2015;23:34-8.
2. Durfee SM, Frates MC, Luong A, Benson CB. The sonographic and color Doppler features of retained products of conception. *J Ultrasound Med* 2005;24:1181-6.
3. Hamerlynck TW, Blikkendaal MD, Schoot BC, Hanstede MM, Jansen FW. An alternative approach for removal of placental remnants: Hysteroscopic morcellation. *J Minim Invasive Gynecol* 2013;20:796-802.
4. Smorgick N, Levinsohn-Tavor O, Ben-Ami I, Maymon R, Pansky M, Vaknin Z. Hysteroscopic removal of retained products of conception following first trimester medical abortion. *Gynecol Minim Invasive Ther* 2017;6:183-5.
5. Zare Z, Zijerdi S. Can ultrasound predict the presence of retained products of conception following first-trimester spontaneous abortion? *Iran Red Crescent Med J* 2009;12:187-9.
6. Smorgick N, Barel O, Fuchs N, Ben-Ami I, Pansky M, Vaknin Z, *et al.* Hysteroscopic management of retained products of conception: Meta-analysis and literature review. *Eur J Obstet Gynecol Reprod Biol* 2014;173:19-22.
7. Hooker AB, Aydin H, Brölmann HA, Huirne JA. Long-term complications and reproductive outcome after the management of retained products of conception: A systematic review. *Fertil Steril* 2016;105:156-64.e1-2.