

## Case Report

# Transvaginal Natural Orifice Transluminal Endoscopic Surgery Hysterectomy in a Woman with Uterine Adenomyosis and Multiple Severe Abdominal Adhesions

Pei-Chen Li<sup>1</sup>, Dah-Ching Ding<sup>1,2</sup>

<sup>1</sup>Department of Obstetrics and Gynecology, Hualien Tzu Chi Hospital, Buddhist Tzu Chi Medical Foundation, Tzu Chi University, <sup>2</sup>Institute of Medical Sciences, Tzu Chi University, Hualien, Taiwan

## Abstract

Natural orifice transluminal endoscopic surgery (NOTES) had been used for many gynecologic surgeries without pelvic adhesions. We report a 30-year-old female with multiple abdominal adhesions underwent NOTES hysterectomy successfully. A 30-year-old female (para 2, gravida 3, abortus 1) presented with menorrhagia and dysmenorrhea. She had multiple abdominal surgical histories. Computed tomography scan revealed multiple adhesions between the abdominal wall and small intestine. On pelvic ultrasonography, an enlarged uterus 8.3 cm × 3.5 cm with adenomyosis was visualized. Because of the extensive intra-abdominal adhesions, we decided to use a transvaginal NOTES approach to perform hysterectomy. We performed the surgery successfully without complication. Pathological examination confirmed adenomyosis of uterus. NOTES hysterectomy may be feasibly and safely performed in gynecologic patients with extensive abdominal adhesions.

**Keywords:** Abdominal adhesions, hysterectomy, natural orifice transluminal endoscopic surgery

## INTRODUCTION

Natural orifice transluminal endoscopic surgery (NOTES) uses the natural orifices, including mouth, vagina, urethra, and rectum, as surgical channels of endoscopy to reach the peritoneal cavity and avoid additional abdominal incisions.<sup>[1]</sup> Since it was first defined by Kalloo *et al.* in 2004, it has been widely applied by general surgeons, gynecologists, urologists, and gastroenterologists all around the world. NOTES has the advantages of avoiding abdominal incisions, eliminating complications of trocar wound, less operative pain, shorter hospital stay, and improved surgical field visibility.<sup>[2]</sup>

In gynecology, the vagina provides direct access to the pelvic cavity and can be easily decontaminated. The transvaginal approach is most frequently used among the routes of NOTES, and it is similar to the previous concept of culdoscopy or ventroscopy.<sup>[3]</sup> Hysterectomy using a transvaginal NOTES approach was reported for the first time by Su *et al.* in 2012.<sup>[4]</sup> Thereafter, a variety of transvaginal NOTES have been reported in benign gynecology and gynecologic

oncology, including adnexal surgery, hysterectomy, and myomectomy.<sup>[5,6]</sup>

To the best of our knowledge, postoperative adhesions may be very challenging to treat and increase hospital visits, repeated interventions, and overall health-care costs. It is regarded as the most common complication of abdominal and pelvic surgery, and previous studies have reported 93% of patients undergoing laparotomy are affected.<sup>[7]</sup> Adhesions lead to significant morbidity, including small bowel obstruction, female infertility, chronic abdominal pain, and increased difficulty with subsequent surgery. Adhesiolysis is associated with a higher risk of inadvertent bowel injury regardless of whether it is performed by laparoscopy or laparotomy. As the development of minimally invasive surgery, it is considered

**Address for correspondence:** Dr. Dah-Ching Ding,  
Department of Obstetrics and Gynecology, Hualien Tzu Chi Hospital,  
Buddhist Tzu Chi Medical Foundation, Chung-Yang, Road, Section 3,  
Hualien 707, Taiwan.  
E-mail: dah1003@yahoo.com.tw

Video available on: [www.e-gmit.com](http://www.e-gmit.com)

### Access this article online

Quick Response Code:



Website:  
[www.e-gmit.com](http://www.e-gmit.com)

DOI:  
10.4103/GMIT.GMIT\_6\_18

This is an open access journal, and articles are distributed under the terms of the Creative Commons Attribution-NonCommercial-ShareAlike 4.0 License, which allows others to remix, tweak, and build upon the work non-commercially, as long as appropriate credit is given and the new creations are licensed under the identical terms.

**For reprints contact:** [reprints@medknow.com](mailto:reprints@medknow.com)

**How to cite this article:** Li PC, Ding DC. Transvaginal natural orifice transluminal endoscopic surgery hysterectomy in a woman with uterine adenomyosis and multiple severe abdominal adhesions. *Gynecol Minim Invasive Ther* 2018;7:70-3.

less adhesiogenic and a feasible technique in a patient with abdominal adhesions. However, laparoscopic adhesiolysis is technically challenging and may not be appropriate in all patients. The patient selection is still a controversial issue. The aim of this article was to present our experience of NOTES hysterectomy in a 30-year-old female with extensive adhesions from previous abdominal surgeries.

## CASE REPORT

A 30-year-old female, G3P2AA1, had suffered from menorrhagia and dysmenorrhea for 4 months. Her operative histories are including appendectomy, adhesion ileus postadhesiolysis, and cesarean sections for twice. Due to multiple abdominal surgical histories, computed tomography (CT) scan of the abdominal cavity was arranged. CT scan revealed multiple adhesions between the abdominal wall and small intestine [Figure 1a and b], and also between the uterine fundus and large bowel [Figure 1c]. The pelvic ultrasonography showed an enlarged uterus 8.3 cm × 3.5 cm with adenomyosis [Figure 1d]. NOTES hysterectomy was suggested due to impossible to entry pelvic cavity through abdominal wall after knowing multiple intestinal adhesions.

The patient received general anesthesia with endotracheal intubation. She was placed in the Trendelenburg position with her legs supported in the stirrups. Urine was drained by indwelling a 12-French Foley catheter. The cervix underwent circumcision by a cold knife. Both anterior and posterior colpotomy was then performed, as is the method for conventional vaginal surgery. After exposing the extraperitoneal space along with broad ligaments and cervical and uterosacral ligaments, bipolar vessel sealer (Ligasure, Covidien, Boulder, CO, USA) was used to clamp and divide. Then, we established the vaginal channel

for endoscopy by applying an Alexis wound retractor (Applied Medical Resources Corp., Rancho Santa Margarita, CA, USA) in the vaginal cavity [Figure 2a]. A surgical glove with one 10 mm and two 5 mm cannulas was inserted through the fingers of the glove [Figure 2a]. The 5 mm, 30° endoscope (Karl Storz, Tuttlingen, Germany) and a 5 mm bipolar Ligasure system (Covidien) were used for the surgery. After adequate pneumoperitoneum, the endoscope was inserted, and then bilateral broad ligament and uterine vessels were identified, coagulation, and cutting. Then, we cut the left side uterine vessels [Figure 2b], broad ligament [Figure 2c], ovarian ligaments [Figure 2d], and fallopian tube sequentially. Then, the right side procedures were done step by step. Dense adhesions were noted at uterine fundal region [Figure 2e] and adhesiolysis was carefully performed [Figure 2f]. After cutting all the pedicles and adhesions, the uterus was removed through the vagina. Vaginal cuff was closed two layer with 2-0 vicryl plus (Ethicon, Somerville, NJ, USA). The pathology proved adenomyosis of uterus.

The recovery course was uneventful and she was discharged from hospital 3 days after surgery.

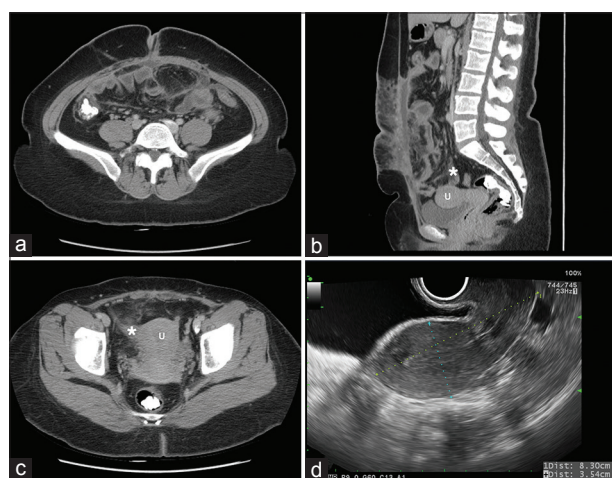Supplementary video related to this article can be found in the supplementary material. <http://www.apagemit.com/page/video/show.aspx?num=172&kind=7&page=1>.

## DISCUSSION

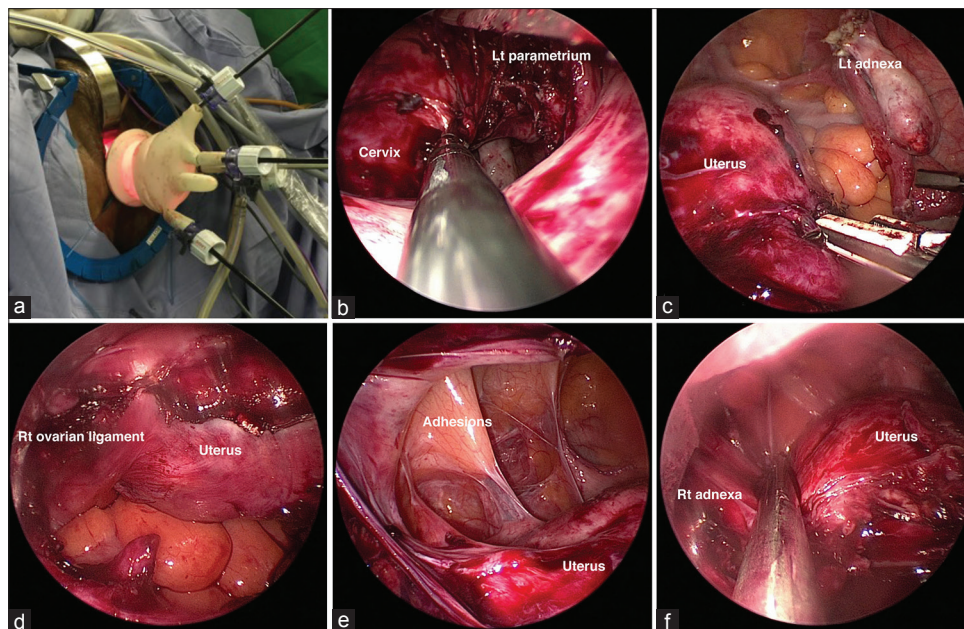
The patient with uterine adenomyosis and multiple abdominal adhesions underwent transvaginal NOTES hysterectomy successfully without major complications, and there was no conversion to conventional laparotomy or laparoscopy. We demonstrated that this technique, which combines conventional colpotomy and NOTES through a vaginal canal can be used in patient with severe abdominal adhesions.

Abdominal adhesions commonly arise after abdominal operations and can give rise to small bowel obstruction, chronic pelvic pain, dyspareunia, and higher complication rates in subsequent operations.<sup>[8]</sup> Laparoscopic adhesiolysis has been used widely and was associated with a reduced rate of overall complications, prolonged ileus, and pulmonary complications compared with open adhesiolysis. However, adhesiolysis by laparoscopy or laparotomy can be very time-consuming and technically difficult due to the narrow surgical field from fibrous bands. In this point of view, NOTES became a feasible and preferred approach to the patient with severe abdominal adhesions because surgeons can reach the pelvic cavity without extensive lysis of abdominal adhesion.

After first published case series of hysterectomy through transvaginal NOTES by Su *et al.* in 2012,<sup>[4]</sup> much research has gone into exploring the techniques and feasibility of NOTES hysterectomy in patients with benign uterine diseases, including total vaginal NOTES hysterectomy,<sup>[1]</sup> vaginally assisted NOTES hysterectomy,<sup>[9,10]</sup> and robot-assisted NOTES hysterectomy.<sup>[11]</sup> Limitations of transvaginal NOTES



**Figure 1:** Image studies of the patient. (a) Coronal view of computed tomography of the abdomen. Note severe adhesions between the intestine and abdominal wall. (b) Sagittal view of computed tomography of the abdomen. Star sign showed intestine adhered to the right posterior surface of the uterus. U: Uterus. (c) Coronal view of the abdomen showing the uterus and surrounding structures. (d) Transvaginal ultrasonography of the uterus showing the internal structure and size.



**Figure 2:** The natural orifice transluminal endoscopic surgery operative images in hysterectomy. (a) Transvaginal natural orifice transluminal endoscopic surgery portal. The anterior and posterior colpotomy was protected by Alexis wound retractor. A surgical glove with four cannulas attached was draped into the retractor. (b) Exploring the left parametrial space and had cutting the uterine artery. (c) Exposure the left adnexal region. (d) Exploring the right adnexal region. (e) Severe pelvic adhesions between the small intestine and right fundal region of the uterus. (f) After dissecting the adhesions. “<http://www.apagemit.com/page/video/show.aspx?num=172&kind=7&page=1>”

mentioned by previous studies included loss of triangulation, instrument clashing, and in particular the inability to have a panoramic view of the pelvis while using a 30° endoscope. Patients with pelvic adhesions, especially at the cul-de-sac are relatively contraindicated for NOTES enucleation due to prolonged surgical time and higher complication rate. Baekelandt recently presented the transvaginal NOTES can be used to perform adhesiolysis combined with left adnexectomy in selected cases in 2015.<sup>[12]</sup> The present study is the first report on the use of transvaginal NOTES hysterectomy in a patient with extensive abdominal adhesions.

As for the concern of increased risk of damaging the ureters or rectum when separating adhesions, preoperative evaluation including pelvic examination and image study should be considered to detect obliterated cul-de-sac. Severe cul-de-sac obliteration is characterized by displaced ureters and severe adhesions to adjacent organs.<sup>[13]</sup> Unexpected cul-de-sac obliteration encountered during the surgical procedure increases the possibility of conversion to transabdominal laparoscopy. Evaluation of pelvic adhesions may be feasible on CT or magnetic resonance imaging (MRI) study, emerging as noninvasive modalities before the surgery. Preoperative CT and MRI may help in deciding the operative approach, facilitate precise preoperative planning, and provide objective evidence to determine the need for adhesiolysis.<sup>[14]</sup> Besides, CT is particularly useful in the diagnosis of adhesive small bowel obstruction or peritoneal inclusion cysts without the presence of typical signs of peritoneal adhesions. One study also reported the specificity of MRI in the detection of pelvic adhesions reached 90%. Accuracy was highest in the anterior cul-de-sac at 88% among all adhesive locations.<sup>[15]</sup> Preoperative CT was

done in this case and showed that intestine adhered to the right posterior surface of the uterus [Figure 1a and b]. The subsequent operative finding revealed dense adhesions at uterine fundal region without cul-de-sac obliteration in this case, which made this patient suitable for NOTES hysterectomy. It also prevents aggravation of abdominal adhesions.

Another concern is vaginal length after NOTES hysterectomy. One prospective observational study showed improved sexual experience after vaginal, total, and subtotal hysterectomy and no difference between them.<sup>[16]</sup> The vaginal length was not correlated with sexual function. One review concluded women can be positively reassured that hysterectomy does not negatively affect sexuality.<sup>[17]</sup>

The advantages of NOTES hysterectomy included the advantages of minimally invasive surgery, invisible scar preventing complications of trocar wound and promoting cosmetic outcomes.<sup>[3]</sup> Besides, in this case, severe abdominal adhesions but without cul-de-sac obliteration can be also the indication of NOTES.

## CONCLUSION

NOTES hysterectomy may be feasibly and safely performed in gynecologic patients with benign pathology. After careful preoperative evaluation, the patient with abdominal adhesions, but without cul-de-sac obliteration can be safely received transvaginal NOTES hysterectomy.

## Declaration of patient consent

The authors certify that they have obtained all appropriate patient consent forms. In the form the patient(s) has/have



given his/her/their consent for his/her/their images and other clinical information to be reported in the journal. The patients understand that their names and initials will not be published and due efforts will be made to conceal their identity, but anonymity cannot be guaranteed.

### Acknowledgment

This work was supported by grants from the Intramural Research Project of Buddhist Tzu Chi General Hospital (TCRD 105-14).

### Financial support and sponsorship

This work was supported by grants from the Intramural Research Project of Buddhist Tzu Chi General Hospital (TCRD 105-14).

### Conflicts of interest

There are no conflicts of interest.

### REFERENCES

1. Baekelandt J. Total vaginal NOTES hysterectomy: A new approach to hysterectomy. *J Minim Invasive Gynecol* 2015;22:1088-94.
2. Jallad K, Walters MD. Natural orifice transluminal endoscopic surgery (NOTES) in gynecology. *Clin Obstet Gynecol* 2017;60:324-9.
3. Lee CL, Wu KY, Su H, Wu PJ, Han CM, Wang CJ, *et al*. Natural orifice transluminal endoscopic surgery in gynecology. *Gynecol Minim Invasive Ther* 2012;1:23-6.
4. Su H, Yen CF, Wu KY, Han CM, Lee CL. Hysterectomy via transvaginal natural orifice transluminal endoscopic surgery (NOTES): Feasibility of an innovative approach. *Taiwan J Obstet Gynecol* 2012;51:217-21.
5. Yoshiki N. Review of transvaginal natural orifice transluminal endoscopic surgery in gynecology. *Gynecol Minim Invasive Ther* 2017;6:1-5.
6. Ding DC, Chu TY, Hong MK. Hysterectomy and ovarian cystectomy using natural orifice transluminal endoscopic surgery: An initial experience at Tzu Chi general hospital. *Tzu Chi Med J* 2017;29:208-12.
7. De Wilde RL, Brölmann H, Koninckx PR, Lunderoff P, Lower AM, Wattiez A, *et al*. Prevention of adhesions in gynaecological surgery: The 2012 European field guideline. *Gynecol Surg* 2012;9:365-8.
8. Brüggmann D, Tchatchian G, Wallwiener M, Münstedt K, Tinneberg HR, Hackethal A, *et al*. Intra-abdominal adhesions: Definition, origin, significance in surgical practice, and treatment options. *Dtsch Arztebl Int* 2010;107:769-75.
9. Lee CL, Wu KY, Su H, Wu PJ, Han CM, Yen CF, *et al*. Hysterectomy by transvaginal natural orifice transluminal endoscopic surgery (NOTES): A series of 137 patients. *J Minim Invasive Gynecol* 2014;21:818-24.
10. Yang YS, Kim SY, Hur MH, Oh KY. Natural orifice transluminal endoscopic surgery-assisted versus single-port laparoscopic-assisted vaginal hysterectomy: A case-matched study. *J Minim Invasive Gynecol* 2014;21:624-31.
11. Lee CL, Wu KY, Su H, Han CM, Huang CY, Yen CF, *et al*. Robot-assisted natural orifice transluminal endoscopic surgery for hysterectomy. *Taiwan J Obstet Gynecol* 2015;54:761-5.
12. Baekelandt J. Poor man's NOTES: Can it be a good approach for adhesiolysis? A first case report with video demonstration. *J Minim Invasive Gynecol* 2015;22:319.
13. Kikuchi I, Takeuchi H, Kuwatsuru R, Kitade M, Kumakiri J, Kuroda K, *et al*. Diagnosis of complete cul-de-sac obliteration (CCDSO) by the MRI jelly method. *J Magn Reson Imaging* 2009;29:365-70.
14. Ghonge NP, Ghonge SD. Computed tomography and magnetic resonance imaging in the evaluation of pelvic peritoneal adhesions: What radiologists need to know? *Indian J Radiol Imaging* 2014;24:149-55.
15. Macer ML, Mathur M, Spektor M, Gysler S, Staib L, Kodaman P, *et al*. Utility of magnetic resonance imaging in the evaluation of intraoperatively confirmed pelvic adhesions. *J Comput Assist Tomogr* 2015;39:896-900.
16. Roovers JP, van der Bom JG, van der Vaart CH, Heintz AP. Hysterectomy and sexual wellbeing: Prospective observational study of vaginal hysterectomy, subtotal abdominal hysterectomy, and total abdominal hysterectomy. *BMJ* 2003;327:774-8.
17. Thakar R. Is the uterus a sexual organ? Sexual function following hysterectomy. *Sex Med Rev* 2015;3:264-78.