



Contents lists available at ScienceDirect

## Gynecology and Minimally Invasive Therapy

journal homepage: [www.e-gmit.com](http://www.e-gmit.com)

## Editorial

## Contained intra-abdominal morcellation: Is it the way forward?



## Background

The USA Food and Drug Administration (FDA) first approved the use of laparoscopic power morcellators for gynecologic surgery in 1995. The use of power morcellators enables surgeons to extract large uteri and/or fibroids whilst retaining the benefits of laparoscopic surgery. The risks associated with using a power morcellator can be categorized into direct and indirect injuries. Direct injuries involve trauma to vessels, nerves, and visceral organs. Indirect injuries include: (1) dissemination of benign disease such as endometriosis and leiomyomas; (2) dissemination of unsuspected malignancy; and (3) delayed or missing diagnosis of cancer. The rate of reported morcellator-related injuries is low: between 1% and 2%.<sup>1,2</sup>

In 2013, a campaign was launched against the use of power morcellators following a case of dissemination of unsuspected leiomyosarcoma (LMS) after elective laparoscopic hysterectomy for presumed fibroids. This has led to a cascade of events worldwide affecting patients, clinicians, and industry.

The US FDA issued the first warning in April 2014 citing the risk of LMS to be as high as 1 in 350. Given that there is no reliable way of distinguishing between a benign fibroid and LMS, the FDA banned the use of power morcellators for laparoscopic myomectomy and hysterectomy. This guidance faced huge criticism, as the data analyzed was small and heterogeneous. Subsequently, the guidance was revised. Worldwide, international health organizations such as the AAGL, ACOG, APAGE, SCOG, and ESGE have issued statements regarding the use of power morcellators. Their recommendations are summarized in [Table 1](#).

## Our response

In light of these concerns and the paucity of robust evidence, how should we, as clinicians, respond? There are simply two main options the clinician could consider: (1) stopping power morcellation altogether; and (2) continue with this technique. Clinicians will need to balance the risk of open abdominal surgery versus the risk of disseminating unsuspected cancer.

*Stop power morcellation*

These events have caused clinicians worldwide to change their practice and stop the use of power morcellation. Since 2013, there was a notable decrease in laparoscopic hysterectomies (−9%) and myomectomies (−17%) performed in our unit.

Are clinicians acting in the patient's best interests in doing so and counselling for open hysterectomy? The answer is likely to be *no*.

**In light of concerns with power morcellation, how should we, as surgeons, respond?**

- a) Stop morcellation
- b) Continue morcellation
  - All cases
  - Selective
  - Contained

Good Level 1 evidence proves that clinicians are exposing patients to higher risks of procedure-related complications such as thromboembolism, increase blood loss, blood transfusions, hernias, and infections.<sup>3,4</sup>

In addition, Siedhoff et al<sup>5</sup> published a decision tree analysis, which predicted that there were more overall hysterectomy-related deaths with open versus laparoscopic hysterectomy (103 vs. 98 per 100,000). This article assumed a hypothetical cohort of 100,000 premenopausal women who underwent hysterectomy for fibroids. There were more LMS-related deaths in laparoscopic hysterectomies (86 vs. 71 per 100,000) and conversely there were more procedure-related deaths in open hysterectomies (32 vs. 12 per 100,000).

Effectively, clinicians choosing the open approach will be subjecting patients to increase surgical morbidity with possibly higher or no difference in mortality rates.

**Table 1**

Summary of international opinions on power morcellation.

## Key points to consider

1. Consent should include the following information:
  - a. Benefits of laparoscopy vs. laparotomy
  - b. Detailed risks of morcellation
  - c. Incidence of unexpected sarcoma  $\approx$  1:350–1:1000
  - d. No reliable preoperative investigations
  - e. Prognosis may worsen if unsuspected cancer is morcellated
2. Morcellation is contraindicated if malignancy is suspected or if known malignancy
3. Morcellation is relatively contraindicated in the perimenopausal and postmenopausal women
4. No reliable preoperative diagnosis
5. Discuss alternative treatment options

Conflicts of interest: No conflicts of interest.

<http://dx.doi.org/10.1016/j.gmit.2016.06.001>

2213-3070/ Copyright © 2016, The Asia-Pacific Association for Gynecologic Endoscopy and Minimally Invasive Therapy. Published by Elsevier Taiwan LLC. This is an open access article under the CC BY-NC-ND license (<http://creativecommons.org/licenses/by-nc-nd/4.0/>).

### Continue power morcellation

Assuming the above, efforts should be made to continue and not abandon power morcellation. Clinicians can choose to continue open morcellation in all cases or perform selective morcellation, both with informed consent.

### All cases

The true incidence of unexpected LMS has yet to be determined. Published studies report the incidence to range from 1:350 to 1:1000. In our unit, our 10 years of retrospective data suggest that the incidence was found to be approximately 1:1000. There were three cases of unexpected sarcoma encountered in 3013 cases of laparoscopic myomectomies performed for presumed fibroids.<sup>6</sup> The incidence of sarcoma increases with age, steadily rising from the 4<sup>th</sup> decade and peaking in the 7<sup>th</sup> decade.

Evidence is also lacking on whether power morcellation itself worsens prognosis. The frequently cited studies evaluating the impact of morcellation on prognosis included both manual and power morcellation. However, presently, it would be prudent to accept that morcellation alone, with or without power, spreads cancerous tissue and may increase recurrence and decrease overall survival rates.<sup>7</sup>

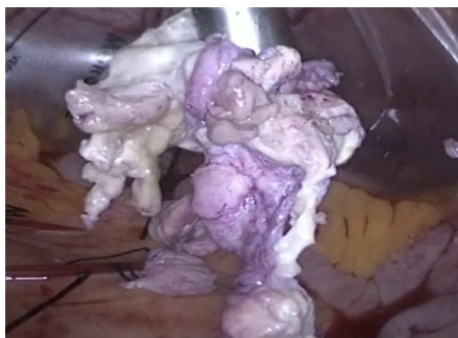### Selected cases

There are no definitive preoperative investigations that are able to differentiate between a benign fibroid and LMS. Radiologic imaging (ultrasound, magnetic resonance, computed tomography), biochemical markers (Ca-125, lactate dehydrogenase), histological (endometrial sampling and needle biopsy) all have poor sensitivity and specificity for LMS. Targeted molecular imaging with the 16-alpha-[18F]-fluoroestradiol (FES) molecule shows some promise but more studies are required. Notably, a small study published by Goto et al concluded a 100% sensitivity and specificity with dynamic magnetic resonance imaging and serum lactate dehydrogenase measurement.<sup>8</sup>

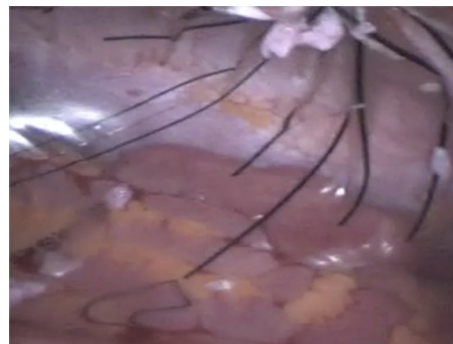
The current guidelines on power morcellation surmise that, by triaging patients into high and low risk categories, clinicians may safely morcellate. However, there will be patients classified as low risk who will have unexpected sarcoma. The majority of patients who are classified as high risk will have benign disease due to the rarity of LMS.

### Future: contained morcellation

Contained morcellation intends to improve the safety profile of power morcellation by reducing the risk of dissemination. The



**Figure 1.** Contained morcellation within a pseudopneumoperitoneum keeping surrounding organs away from the operating field.



**Figure 2.** Tissue fragments remain within the bag after morcellation allowing ease of tissue removal and dissemination of tissue.

concept behind contained morcellation is not new. Clinicians have been modifying existing tissue retrieval bags in which to perform morcellation. This is to avoid spillage or spread of tissue within the abdominal cavity. The additional benefit of using a contained system aids the ease of removal of tissue fragments after morcellation. It also creates a safe operating field by keeping the bowels away from the morcellator (Figures 1 and 2).

There are now various bags on the market specifically designed for use with power morcellators. The More-Cell-Safe system and MorSafe bag has achieved the CE certification and more recently the PneumoLiner gained US FDA approval. The choice of bag is based on surgeon preference but should take into account the following:

- 1) The material used to make the bag has been shown to be impermeable to tissue and liquids at sufficient pressure.
- 2) The material should be clear or translucent to allow visualization of surrounding organs.
- 3) The bag is large enough to accommodate the specimen and allow for adequate insufflation to obtain a good operating field or pseudopneumoperitoneum; i.e., distance between morcellator and surrounding organs.
- 4) The design of the bag allows for the laparoscope to be inserted to let morcellation to be performed under direct vision.
- 5) The bag is easy to use to limit additional operating time.
- 6) The bag is of minimal additional cost to the patient.

### Conclusion

Contained morcellation allows the surgeon to safely continue intra-abdominal manual or power morcellation without the absolute need for triage. It should not be undertaken in cases with known or suspected malignancy. Arguably, there is no robust evidence to support contained morcellation, although logical sense dictates that it will probably minimize the risk of dissemination of both benign and malignant tissue. Long-term multicenter prospective data should be collected to evaluate its use.

### References

1. Milad MP, Milad EA. Laparoscopic morcellator-related complications. *J Minim Invasive Gynecol.* 2014;21:486–491.
2. Brölmann H, Tanos V, Grimbizis G, et al. Options on fibroid morcellation: a literature review. *Gynecol Surg.* 2015;12:3–15.
3. Bhav Chittawar P, Franik S, Pouwer AW, Farquar C. Minimally invasive surgical techniques versus open myomectomy for uterine fibroids. *Cochrane Syst Rev.* 2014;10:CD004638.
4. Aarts JWM, Nieboer TE, Johnson N, et al. Surgical approach to hysterectomy for benign gynaecological diseases. *Cochrane Syst Rev.* 2015;8:CD003677.

5. Siedhoff MT, Wheeler SB, Rutstein SE, et al. Laparoscopic hysterectomy with morcellation vs abdominal hysterectomy for presumed fibroid tumors in premenopausal women: a decision analysis. *Am J Obstet Gynecol*. 2015;212:591.e1–591.e8.
6. Chin H, Ng XHA, Chern SMB. Power morcellation—An emerging risk complicating minimally invasive surgery for uterine mesenchymal neoplasms. *Gynecol Minim Invas Ther*. 2016;5:109–111.
7. Bogani G, Cliby WA, Aletti GD. Impact of morcellation on survival outcomes of patients with unexpected uterine leiomyosarcoma: a systematic review and meta-analysis. *Gynecol Oncol*. 2015;137:167–172.
8. Goto A, Takeuchi S, Sugimura K, Maruo T. Usefulness of Gd-DTPA contrast-enhanced dynamic MRI and serum determination of LDH and its isozymes in the differential diagnosis of leiomyosarcoma from a degenerated leiomyoma of the uterus. *Int J Gynecol Cancer*. 2002;12:354–361.

Alexandriia See\*, Bernard Chern  
KK Women's and Children's Hospital, Singapore

\* Corresponding author. KK Women's and Children's Hospital,  
Singapore 229899, Singapore.  
E-mail address: [alexandriia.see.ta@kkh.com.sg](mailto:alexandriia.see.ta@kkh.com.sg) (A. See).

31 May 2016  
Available online 10 August 2016