



Contents lists available at ScienceDirect

Gynecology and Minimally Invasive Therapy

journal homepage: www.e-gmit.com

Review article

Single-incision laparoscopic myomectomy: A review of the literature and available evidence



Naoyuki Yoshiki*

Comprehensive Reproductive Medicine, Systemic Organ Regulation, Graduate School of Medical and Dental Sciences, Tokyo Medical and Dental University, Tokyo, Japan

ARTICLE INFO

Article history:

Received 22 August 2015

Received in revised form

1 February 2016

Accepted 2 February 2016

Available online 18 April 2016

Keywords:

laparoendoscopic single-site surgery

laparoscopic suturing

natural orifice transluminal endoscopic surgery

single-incision laparoscopic myomectomy

single-incision laparoscopic surgery

ABSTRACT

Single-incision laparoscopic surgery (SILS) has become more feasible and safer for the patient by improvement in conventional laparoscopic techniques and availability of more advanced instruments. To date, there are many publications regarding having applied this technique to most benign gynecologic disorders. However, with regard to single-incision laparoscopic myomectomy, there are only a handful of publications. Researchers in the literature show that single-incision laparoscopic myomectomy is a safe and effective alternative to conventional laparoscopic myomectomy in a selected group of women. However, all researchers have emphasized the difficulty of intracorporeal suturing through a single port. In the future, a barbed suture and the use of a culdoscope may be useful to perform single-incision laparoscopic myomectomy. The integration of SILS and natural orifice transluminal endoscopic surgery will certainly contribute to a wider application of this approach.

Copyright © 2016, The Asia-Pacific Association for Gynecologic Endoscopy and Minimally Invasive Therapy. Published by Elsevier Taiwan LLC. This is an open access article under the CC BY-NC-ND license (<http://creativecommons.org/licenses/by-nc-nd/4.0/>).

Introduction

Uterine fibroids (also called leiomyomas or myomas) are the most common disorder of the uterus among women of reproductive age. The majority of uterine fibroids are symptomless. However, the symptoms of uterine fibroids can be sometimes manifested and disturb women. The problem for women of reproductive age is that uterine fibroids can cause sterility.

The most radical treatment for uterine fibroids is hysterectomy, which is performed only to women who will not give birth from now on. However, as a modern trend, women seeking the possibility of treatment that preserve the uterus have emerged because the uterus came to be regarded as a regulator and controller of important physiological functions, a sexual organ, a source of energy and vitality, and a maintainer of youth and attractiveness psychologically. Therefore, for women who wish to preserve fertility, expectant management, medical therapy,¹ surgical

intervention,² uterine artery embolization,³ uterine artery ligation,⁴ uterine vessel occlusion,⁵ ablative techniques,⁶ or magnetic resonance-guided focused ultrasound surgery,³ etc. are potential alternatives to hysterectomy. However, differential diagnosis of malignant-type leiomyosarcoma should be made carefully if conservative treatment is planned.

In past years, the management of uterine fibroids has increased dramatically by progress of medical technology, and a multidisciplinary approach is frequently applied. In addition, relatively less invasive procedures are designed to preserve the uterus regardless of future fertility. In general, the choice of treatment of uterine fibroids is performed in consideration of the patient's age and preference, the reason for treatment, and the issue of fertility preservation. Myomectomy is still a standard treatment for women with symptomatic uterine fibroids seeking fertility preservation.⁷ At present, laparoscopic myomectomy has several advantages over abdominal myomectomy and even over myomectomy by minilaparotomy.⁸ This review is limited to discussing laparoscopic myomectomy in the management of symptomatic uterine fibroids.

Advances in technology over the past several decades have created more surgical options for gynecologists and their patients. Surgeries that were performed with laparotomy in the past can now be performed with minimally invasive procedures such as minilaparotomy and laparoscopy. Laparoscopic surgery has

Conflicts of interest: The author declares no conflicts of interest relevant to this article.

* Corresponding author. Comprehensive Reproductive Medicine, Systemic Organ Regulation, Graduate School of Medical and Dental Sciences, Tokyo Medical and Dental University, 1-5-45, Yushima, Bunkyo-ku, Tokyo 113-8519, Japan.

E-mail address: n.yoshiki.crm@tmd.ac.jp.

<http://dx.doi.org/10.1016/j.gmit.2016.02.004>

2213-3070/Copyright © 2016, The Asia-Pacific Association for Gynecologic Endoscopy and Minimally Invasive Therapy. Published by Elsevier Taiwan LLC. This is an open access article under the CC BY-NC-ND license (<http://creativecommons.org/licenses/by-nc-nd/4.0/>).

occupied a central position in the management of benign and malignant conditions in gynecology. In recent years, various efforts such as reducing the port size and/or number have been made to further minimize the invasiveness of conventional laparoscopy. As a result of these efforts, single-incision laparoscopic surgery (SILS) has been created as a further development of conventional laparoscopy.^{9–15} This procedure is performed through a single incision at the umbilicus, reducing the morbidity of additional incisions and improving the final cosmetic outcome. When there is more than one reasonable surgical approach, it is necessary to consider the patient's interest on cosmetic aspects. Therefore, in this review, it is discussed with a focus on single-incision laparoscopic myomectomy, which is superior in cosmesis.

Development of SILS

With the success of laparoscopic surgery, most surgeons would agree that minimally invasive surgery in appropriately selected patients provides a clear advantage in terms of both patient outcome and cost. One of the recent remarkable developments in the field of minimally invasive surgery includes advances in SILS. This minimally invasive procedure is performed through a single incision at the umbilicus. SILS has an advantage to further enhance the cosmetic benefits of minimally invasive surgery while minimizing the potential risks and morbidity associated with multiple ports. Although there are technically difficult points such as complex intracorporeal maneuvers, lack of instrument triangulation, limited traction of tissue, and external crowding and clashing, SILS has been successfully performed. In addition, SILS has developed rapidly as an alternative to scarless natural orifice transluminal endoscopic surgery (NOTES), which still remains experimental.

Devices used for SILS

Specialized equipment for SILS is divided into three broad categories: access ports, operating instruments, and optics.

Access ports

SILS may be typically performed by means of three approaches. The first is to make a single incision in the skin and multiple incisions in the fascia, with small bridges cut between the fascial incisions to enable organ retrieval. With this approach, multiple 5- to 12-mm trocars are inserted next to each other to access the abdominal cavity. The second is called “home-made single-port system”; it consists of a wound retractor and a surgical glove. The wound retractor is composed of a distal ring, a proximal ring, and a cylindrical connecting sleeve. The outer ring of the wound retractor is wrapped around the wrist portion of the glove, and the digit parts of the glove are used as working channels for laparoscopic instruments and camera. The elastic nature of the glove allows it to obtain a good position on the ring, create an airtight seal, and maintain pneumoperitoneum. The third approach uses a specialized access port with multiple channels, through which multiple instruments and optics can be introduced. These commercially available specialized access ports are described below:

SILS port

SILS port (Covidien, Mansfield, MA, USA; [Figure 1](#)) is a multi-channel access port that allows up to three laparoscopic instruments (three 5-mm cannulas or two 5-mm and one 12-mm cannula) to be used simultaneously through separate flexible channels.

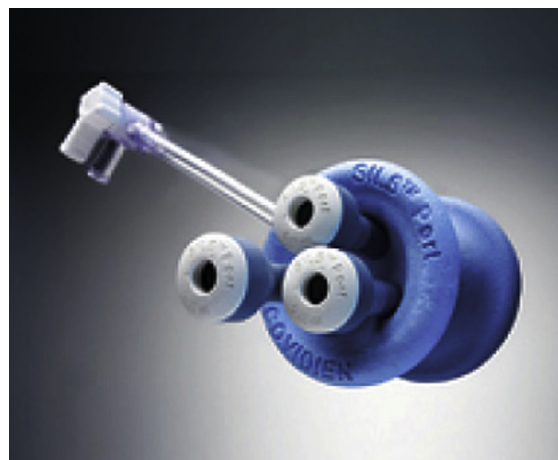

Figure 1. SILS port (Covidien, Mansfield, MA, USA).

GelPort and GelPOINT systems

The GelPort and newer generation GelPOINT systems (Applied Medical, Rancho Santa Margarita, CA, USA; [Figure 2](#)) consist of a combination of the rigid ring of the Alexis wound retractor with a GelSeal cap that maintains pneumoperitoneum during multiple instruments exchange. The GelPOINT platform is a dedicated modification of the GelPort system available for single-port laparoscopy in which, along with the GelSeal cap, four small cannulas are provided by the manufacturer for easier insertion of laparoscopic instruments through the gel interface.

AirSeal dynamic pressure system

AirSeal ports (SurgiQuest, Orange, CT, USA) use air pressure to create pneumoperitoneum. The new AirSeal port oval design is advantageous for single-port laparoscopy because it enables better access for multiple instruments.

Single-site laparoscopy access system

The single-site laparoscopy access system (Ethicon Endo-Surgery, Cincinnati, OH, USA) is an abdominal access system




Figure 2. GelPort and GelPOINT systems (Applied Medical, Rancho Santa Margarita, CA, USA).

composed of a fixed-length retractor and a seal cap with accessories (retractor insertion tool and reducer cap).

TriPort and QuadPort

TriPort and QuadPort (Advanced Surgical Concepts, Bray, County Wicklow, Ireland) are multichannel access ports. TriPort has two 5-mm ports and one 12-mm port, and can be used with fascial incisions ranging from 12 mm to 25 mm. QuadPort is similar to the TriPort, but provides four ports: one 5-mm port, one 15-mm port, and two 10-mm ports. The device can be used with fascial incisions ranging from 25 mm to 60 mm.

S-Portal X-Cone and Endocone

S-Portal X-Cone (Figure 3) and Endocone (Karl Storz, Tuttlingen, Germany) are reusable single-port access devices. The devices when used in tandem with specially designed curved instruments enhance the triangulation in single-port access surgery.

Operating instruments

The cornerstones of conventional laparoscopic surgery are triangulation and retraction, which are achieved by ports placed far apart. Two of the biggest factors that limit the use of a SILS technique are instrument crowding and lack of triangulation. Standard hand instruments for use in conventional laparoscopy are rigid in design and allow only 4 degrees of freedom, thus limiting the surgeon's dexterity. Articulation is designed to overcome one of the challenges inherent in SILS, that is, decreased triangulation of the instruments. The following are the most common specialized instruments currently on the market for facilitating SILS.

RealHand instruments

RealHand high-dexterity instruments (Novare Surgical Systems, Cupertino, CA, USA; Figure 4) are 5-mm instruments in which the handle is connected to the tip by several cables, which enables 360° articulation that mimics the movement of the surgeon's hand and, therefore, provides 7 degrees of freedom of movement.

Autonomy Laparo-Angle instruments

Similar to the RealHand instruments, Autonomy Laparo-Angle instruments (Cambridge Endoscopic Devices, Framingham, MA,



Figure 3. S-Portal X-Cone and curved instruments (Karl Storz, Tuttlingen, Germany).

USA; Figure 5) provide a 360° articulating head that mimics the surgeon's movements. Unlike the RealHand instruments, these instruments include a mechanism to rotate the instrument head after locking at any angle and a finger socket to open and close the distal jaws.

SILS kit and SILS hand instruments

The SILS kit (Covidien; Figure 6) includes the SILS port and Roticulator instruments with distal ends, which have a limited range of movement of 0–80°. As the distal end is pushed out from its outer sheath, the angle of the extended bent portion increases. The handle also enables the surgeon to rotate the distal instrument 360°, similar to what is possible with conventional laparoscopic instruments. SILS hand instruments offer infinite positions of dynamic articulation within a semihemispherical space and can lock the instrument shaft and angle through an articulation lock lever.

S-Portal curved instruments

S-Portal curved instruments (Karl Storz; Figure 3) represent the first generation of curved coaxial instruments with single or double bending. These instruments have the advantage of being reusable.

Optics

Conventional 5- and 10-mm cameras can be used for SILS. The use of conventional laparoscopic cameras, however, increases instrument crowding, hence specific laparoscopes for SILS have been developed.

The 30°-forward-oblique Hopkins II laparoscope

The 30°-forward-oblique Hopkins II laparoscope (Karl Storz) is 5 mm in diameter, 50 cm in length, and includes a high-definition video resolution. This laparoscope offsets the instrument length during surgery, and reduces crowding and enhances the viewing angle.

The deflectable-tip EndoEYE video laparoscope

The deflectable-tip EndoEYE video laparoscope (Olympus America, Center Valley, PA, USA; Figures 7A and 7B) has an outer diameter of 5 mm for a standard video resolution camera, and 10 mm for a high-definition video resolution camera. The distal tip is flexible and hosts the camera, enabling enhanced range of angulation. The major advantage is that less movement is necessary at the port site to move the camera, which reduces collision with other instruments in the limited space.

The Ideal Eyes HD articulating laparoscope

The Ideal Eyes HD articulating laparoscope (Stryker, Kalamazoo, MI, USA) has an inline design that provides ~ 100° of flexion in all directions.

The EndoCAMEleon

The EndoCAMEleon (Karl Storz; Figure 8A and 8B) is a new laparoscope with variable direction of view. It allows the user to adjust the viewing direction quickly and easily between 0° and 120°, as the conditions require.



Figure 4. RealHand instruments (Novare Surgical Systems, Cupertino, CA, USA).

Development of SILS in gynecology

Single-port minimally invasive surgery in gynecology began in 1969. In the 1970s, several gynecologists performed laparoscopic tubal sterilization through a single umbilical incision.¹⁶ The ability to perform complex procedures through a single incision has only recently been realized. Former limitations included limited instrumentation, access ports and optics. In recent years, however, SILS has become more feasible and safer for the patient by improvement in conventional laparoscopic techniques and availability of more advanced instruments. To date, there are many publications regarding having applied this technique to most benign gynecologic disorders. Lee et al¹⁷ evaluated retrospectively the use of SILS in benign gynecologic diseases and its effect on

surgical outcomes. They observed increased use of SILS in the time: 29% in the first cases reviewed; 62% in the second, 72% in the third, 71% in the fourth, and 86% in the last 100 cases, with a gradual reduction of laparotomy and multiport laparoscopy.

Single-incision laparoscopic myomectomy

Despite improvement in techniques and development of instrumentation for SILS, there are only a handful of publications describing single-incision laparoscopic myomectomy. By searching PubMed for keywords including “single incision laparoscopic myomectomy,” “single site laparoscopic myomectomy,” “single port laparoscopic myomectomy,” and “embryonic natural orifice transumbilical endoscopic myomectomy,” a total of 16 articles were

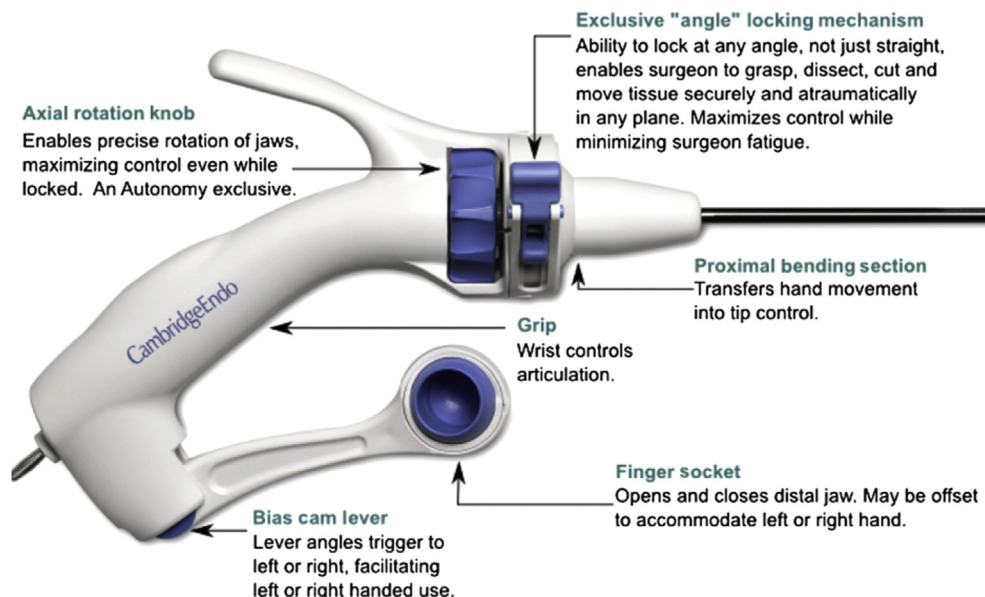


Figure 5. Autonomy Laparo-Angle instruments (Cambridge Endoscopic Devices, Framingham, MA, USA).

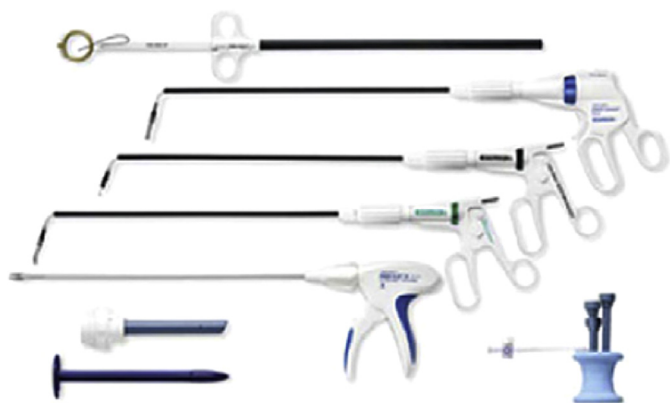

Figure 6. SILS kit with Roticulator instruments (Covidien, Mansfield, MA, USA).

identified.^{2,18–32} Tables 1 and 2 show single-incision laparoscopic myomectomy procedures and surgical outcomes, respectively. Researchers in the literature show that single-incision laparoscopic myomectomy is a safe and effective alternative to conventional laparoscopic myomectomy in a selected group of women. The most important technique in laparoscopic myomectomy is intracorporeal suturing for uterine closure, but this maneuver is the most difficult to acquire. The technique of laparoscopic myomectomy is possible with single-port access, however, most surgeons find a suturing technique difficult through a single port. In fact, single-incision laparoscopic suturing technique has the difficulty with an extra dimension, and all researchers have emphasized the difficulty of intracorporeal suturing through a single port. Therefore, in order to avoid the technical difficulties that often accompany intracorporeal suturing of the uterine wall defects during




Figure 7. (A) The deflectable-tip EndoEYE video laparoscope with coaxial light cable (Olympus America, Center Valley, PA, USA); (B) deflectable-tip EndoEYE (Olympus America, Center Valley, PA, USA).




Figure 8. (A) The EndoCAMeleon (Karl Storz, Tuttlingen, Germany). The arrow indicates the knob allowing the viewing angle to be changed. (B) The optomechanics within the tip of the EndoCAMeleon (Karl Storz, Tuttlingen, Germany). The arrow describes the range of lens movement in the casing of the endoscope.

single-incision laparoscopic myomectomy, alternative methods have been developed (Table 1). These alternative methods are barbed suture,^{18–21} “bottom knot,”²² extracorporeal knots,^{23,24} suture using an Endo Stitch device (Covidien),²⁵ a modified suture technique using Hem-o-lock ligation clips,²⁶ or intracorporeal knots using an articulating device.^{27–30} However, the author² reported intracorporeal suturing using conventional, rigid, and straight instruments through a single port. They described that with experience came an increased ability to perform conventional smooth suture in single-incision laparoscopic myomectomy. An obvious advantage of single umbilical access is that it is much easier to remove specimens through a larger incision, compared with a smaller incision used in conventional approach. All researchers reported that removed myomas were extracted transumbilically.

Initial clinical study

Kim et al²² reported the first case series of single-incision laparoscopic myomectomy using a new single-port transumbilical morcellation system. A single-port system created with a wound retractor and a surgical glove made transumbilical myoma morcellation and extraction possible. The wound retractor widens an umbilical incision, which enables simultaneous transit of several laparoscopic instruments including a conventional electromechanical morcellator that can be as large as 15 mm into a small umbilical incision. Their study established that in single-incision laparoscopic myomectomy, it could be more difficult to handle instruments for cleavage of large myomas compared with conventional laparoscopic myomectomy. However, they concluded that the more often single-incision laparoscopic myomectomy was performed, the more feasible it should become.

Table 1
Single-incision laparoscopic myomectomy procedures. ^c

Source, year	Study type	No. of patients	Access ports	Specialized instruments	Optics	Suturing	Operative time (min)	Complications, including conversion to multiport laparoscopy or laparotomy
Lee et al, ³⁰ 2015	Retrospective	161	Wound retractor & surgical glove	RealHand or Autonomy Laparo-Angle (for suturing)	Rigid 0° laparoscope	Intracorporeal knots using articulating device	95.2 ^b	1 conversion to 2-port
Song et al, ²¹ 2015	Prospective comparative	60	Multichannel port	No use	NA	Barbed suture vs. smooth suture	69 vs. 91 ^a	2 conversion to laparotomy
Lee et al, ²⁹ 2014	Case series	100	Wound retractor & surgical glove	RealHand or Autonomy Laparo-Angle (for suturing)	Rigid 0° laparoscope	Intracorporeal knots using articulating device	116.3 ^b	3 (1 voiding difficulty, 1 thigh numbness, 1 wound discharge), 1 conversion to 2-port
Kim et al, ²⁴ 2014	Prospective matched case–control	45	GelPort	Autonomy Laparo- Angle & RealHand	Telescope	Extracorporeal knots	135 ^a	5, 3 conversion to 2-port
Kim et al, ²⁸ 2014	Retrospective comparative	59	Wound retractor & surgical glove	Autonomy Laparo-Angle (for suturing)	Flexible 30° laparoscope	Intracorporeal knots using Autonomy Laparo-Angle	115.7 ^b	2 wound infections, 1 conversion to 2-port
Yoon et al, ²⁷ 2014	Case series	28	Wound retractor & surgical glove	Roticulator (for suturing)	Rigid 30° video laparoscope	Intracorporeal knots using Roticulator	131 ^a	1 conversion to 2-port
Choi et al, ²⁶ 2014	Retrospective comparative	55	Wound retractor & surgical glove	Roticulator	Rigid 0° laparoscope	Modified suture technique using Hem-o-lock ligation clips	103.5 ^b	None
Han et al, ³¹ 2013	Retrospective matched case–control	10	Wound retractor & surgical glove	No use	0° laparoscope	Smooth suture	196.5 ^a	None
Yoshiki et al, ² 2011	Case series	12	Wound retractor & surgical glove	No use	Deflectable-tip EndoEYE video laparoscope	Smooth suture	100 ^b	None
Mereu et al, ²⁰ 2011	Case report	1	S-Portal X-Cone	Flexible monopolar hook & curved instrument (for suturing)	30° Hopkins II laparoscope	Barbed suture using curved instrument	94	None
Lim et al, ²⁵ 2011	Case report	1	Wound retractor & surgical glove	Roticulator	Laparoscope with incorporated light source within camera head	Suture using Endo Stitch	230	None
Jackson & Einarsson, ¹⁹ 2011	Description of surgical technique	NA	3 5-mm trocars	No use	Bronchoscope with 30° optic	Barbed suture	60–120	NA
Ramesh et al, ³² 2011	Case report	1	SILS port	No use	NA	Continuous suture	130	None
Lee et al, ²³ 2010	Case series	15	GelPort	Autonomy Laparo-Angle & RealHand	Telescope	Extracorporeal knots	81 ^b	1 conversion to 2-port
Kim et al, ²² 2010	Case series	15	Wound retractor & surgical glove	No use	Rigid 0° or 30° laparoscope	“Bottom knot”	96.7 ^b	None
Einarsson, ¹⁸ 2010	Case report	1	3 5-mm trocars	No use	Bronchoscope with 30° optic	Barbed suture	115	None

NA = not available.

^a Median.

^b Mean.

^c All optics are 5 mm in diameter.

Table 2
Surgical outcomes of single-incision laparoscopic myomectomy.

Source, year	No. of patients	No. of myomas per patient	Size (cm)	Weight (g)	Type (%)	Location	Blood loss (mL)	Hemoglobin drop (g/dL)	Hospital stay (d)
Lee et al, ³⁰ 2015	161	1.4 ^b	6.9 ^b	131.6 ^b	Intramural 142 (88.2) Subserosal 10 (6.2) Submucosal 4 (2.5) Intraligamentary 5 (3.1)	NA	85.5 ^b	1.8 ^b	2.1 ^b
Song et al, ²¹ 2015	60	1 ^a	6.6 ^b	NA	NA	Anterior 24 (40) Posterior 24 (40) Fundal or lateral 12 (20)	15–450	2.0 ^b	3 ^a
Lee et al, ²⁹ 2014	100	1.6 ^b	6.6 ^b	136.9 ^b	Intramural 80 (80) Subserosal 12 (12) Submucosal 5 (5) Intraligamentary 3 (3)	Anterior 36 (36) Posterior 24 (24) Fundal 30 (30) Lateral 10 (10)	94.6 ^b	1.8 ^b	2.0 ^b
Kim et al, ²⁴ 2014	45	1.6 ^b	5.4 ^a	NA	Intramural 44 (60.3) Subserosal 29 (39.7)	Anterior 30 (41.1) Posterior 25 (34.2) Fundal 12 (16.4) Lateral 6 (8.2)	NA	1.9 ^a	5 ^a
Kim et al, ²⁸ 2014	59	1.6 ^b	7.3 ^b	173.9 ^b	Intramural 48 (81.4) Subserosal 7 (11.9) Intraligamentary 4 (6.8)	NA	171.0 ^b	1.8 ^b	2.1 ^b
Yoon et al, ²⁷ 2014	28	1.3 ^b	6 ^a	NA	Intramural 9 (25.7) Subserosal 19 (54.3) Intraligamentary 7 (20)	Anterior 21 (60) Posterior 4 (11.4)	65 ^a	2 ^a	3 ^a
Choi et al, ²⁶ 2014	55	1.2 ^b	6.8 ^b	NA	Intramural 36 (65.5) Subserosal 12 (21.8) Submucosal 7 (12.7)	Anterior 26 (47.3) Posterior 13 (23.6) Fundal 7 (12.7) Broad ligament 9 (16.4)	*138.9 ^b	1.57 ^b	2.9 ^{b,*}
Han et al, ³¹ 2013	10	1.1 ^b	7 ^a	145 ^a	Intramural 5 (50) Subserosal 5 (50)	Anterior 7 (70) Posterior 1 (10) Fundal 2 (20)	100 ^a	NA	3 ^{a,**}
Yoshiki et al, ² 2011	12	1.9 ^b	NA	78 ^b	Intramural 4 (33.3) Subserosal 6 (50) Submucosal 2 (16.7)	NA	<10	NA	NA
Lee et al, ²³ 2010	15	1.2 ^b	5.5 ^b	NA	Intramural 10 (55.6) Subserosal 8 (44.4)	Anterior 8 (44.4) Posterior 6 (33.3) Fundal 2 (11.1) Lateral 2 (11.1)	NA	1.1 ^b	3.1 ^b
Kim et al, ²² 2010	15	1.6 ^b	6.1 ^b	NA	Intramural 7 (46.7) Subserosal 7 (46.7) Intraligamentary 1 (6.7)	NA	NA	1.8 ^b	3.1 ^b

* Statistically significant decrease compared with conventional laparoscopic myomectomy.

** Statistically significant increase compared with conventional laparoscopic myomectomy.

NA = not available.

^a Median.

^b Mean.

Characteristics of myomas

Lee et al²³ reported their initial experience with single-incision laparoscopic myomectomy using the GelPort system in 15 patients with a symptomatic subserosal or superficial intramural myoma measuring ≤ 8 cm. They concluded that single-incision laparoscopic myomectomy was feasible in selected patients with symptomatic myomas, to maximize the cosmetic benefits and to minimize wound-related morbidity, but also concluded that the development of advanced laparoscopic instruments designed specifically for single-incision laparoscopic myomectomy and increased research regarding patient selection based on objective evidence were required. Yoon et al²⁷ described the characteristics of 35 myomas in 28 patients who underwent single-incision laparoscopic myomectomy. They concluded that careful selection of patients considering the type and location of myomas was important for successful single-incision laparoscopic myomectomy. They found that myomas located in the anterior wall, subserosal or intraligamentary myomas were relevant for single-incision laparoscopic myomectomy. Lee et al²⁹ recently published a series of 100 women who underwent single-incision laparoscopic myomectomy without any combined surgery. In their study, single-incision laparoscopic myomectomy showed acceptable surgical outcomes

for operative time, estimated blood loss, postoperative hospital stay, and complications. They found no significant technical differences according to myoma location. This result was obtained because the approaches of all devices inserted through the umbilicus (usually above enough from the uterus) were similar in most cases. They concluded that single-incision laparoscopic myomectomy was safe and acceptable for various myoma sites and sizes up to 12 cm, and that intracorporeal suture-tying and transumbilical morcellation were key technical points of this procedure.

Surgical outcomes

Han et al³¹ were the first to report a comparative study of single-incision laparoscopic myomectomy versus conventional laparoscopic myomectomy with a small sample size. They have reported that 10 single-incision laparoscopic myomectomy procedures resulted in comparable surgical outcomes, with superior cosmesis but with longer operative time than 10 conventional laparoscopic myomectomy procedures. Kim et al²⁸ also published a study comparing surgical outcomes and postoperative pain between single-incision laparoscopic myomectomy and conventional laparoscopic myomectomy. A total of 118 patients who underwent single-incision laparoscopic myomectomy or conventional

laparoscopic myomectomy were included in the study (59 in the single-incision laparoscopic myomectomy group and 59 in the conventional laparoscopic myomectomy group). Considering the surgeon's learning curve for single-incision laparoscopic myomectomy, they collected the data after the initial 100 single-incision laparoscopic myomectomy procedures were performed. Surgical outcomes such as operative time, estimated blood loss, postoperative hemoglobin drop, and postoperative hospital stay were not statistically different between the two groups. Postoperative pain scores assessed at 1 hour, 6 hours, and 24 hours were not significantly different between the two groups. Their results were different from those of Han et al.,³¹ who showed that operative time for single-incision laparoscopic myomectomy was significantly longer than that for conventional laparoscopic myomectomy. They speculated that the main reason for the difference between the previous and the present study might be the surgeon's experience and learning curve. The study by Han et al.³¹ was a report after an initial experience with 10 cases; thus, the initial learning curve may have not been overcome at the time of the analysis. They concluded that surgical outcomes and perioperative complications of single-incision laparoscopic myomectomy were comparable with those of conventional laparoscopic myomectomy.

Learning curve

Lee et al.³⁰ recently assessed the learning curve for single-incision laparoscopic myomectomy via a graph based on operative time according to the sequence of operation. A total of 161 patients were divided into four groups according to their operation sequence; each group had the same number of patients ($n = 40$) except for the first group ($n = 41$). There were no significant differences in basal characteristics between the four groups. In the comparison of surgical outcomes, no differences were noted among the four groups. The mean operative times of the four groups were 112.0 minutes, 92.8 minutes, 83.7 minutes, and 90.0 minutes, respectively. Operative time decreased significantly in the second, third, and fourth groups compared with that in the first group. Results from their study suggested that proficiency for single-incision laparoscopic myomectomy, defined as the point at which the slope of the learning curve became less steep abruptly from the steepest slope, was achieved after ~ 45 operations.

Suturing techniques

Choi et al.²⁶ compared operative outcomes of single-incision laparoscopic myomectomy using a modified suture technique with Hem-o-lock ligation clips (Choi's LM) and conventional laparoscopic myomectomy in the treatment of symptomatic myomas. A total of 157 patients who underwent Choi's LM or conventional laparoscopic myomectomy were included in the study (55 in Choi's LM and 102 in conventional laparoscopic myomectomy). The data demonstrated that when the size and number of myomas were similar, Choi's LM was associated with shorter operative time, less blood loss, and less postoperative pain than conventional laparoscopic myomectomy. One of the important findings of their study was that Choi's LM was less painful than conventional laparoscopic myomectomy, which was different from that of Kim et al.²⁸ They speculated that reduced pain could be attributed in part to reduced operative time and bleeding, and to a single-port incision. They found that in addition to easy extraction through the umbilical incision site, the modified suture method could also contribute to reduced operative time and bleeding. Song et al.²¹ recently published a prospective comparative study including 60 consecutive patients who underwent single-incision laparoscopic myomectomy at three institutions. The data for the first 30 patients, who

underwent surgery using traditional intracorporeal suture, were compared with the data for the next 30 patients, who underwent surgery using an absorbable unidirectional knotless barbed suture device to repair the uterine wall defects. Patient baseline characteristics were similar between the two study groups. The use of barbed suture significantly reduced suturing time for treating the uterine wall defects, as well as total operative time. However, no differences were observed between the groups for the other operative time segments, including myoma enucleation time and morcellation time. The use of barbed suture was also associated with less operative blood loss and less technical difficulty compared with traditional suture. As surgeons seek more time- and labor-effective surgical methods, they were confident that barbed suture would be received as a promising suturing technique in single-incision laparoscopic myomectomy.

Obstetric outcomes

Kim et al.²⁴ recently compared operative and obstetric outcomes of single-incision laparoscopic myomectomy versus conventional laparoscopic myomectomy. Forty-five patients of the single-incision laparoscopic myomectomy group were matched 1:2 with 90 patients who underwent conventional laparoscopic myomectomy. There were no significant differences between the two groups in demographic characteristics, operative results, and obstetric outcomes. Eight women in the single-incision laparoscopic myomectomy group and 9 women in the conventional laparoscopic myomectomy group achieved pregnancy. There were no statistically significant differences between the groups in terms of the pregnancy rate. They concluded that obstetric outcomes after single-incision laparoscopic myomectomy did not differ from those after conventional laparoscopic myomectomy.

Cosmesis

When deciding on a minimally invasive approach for gynecologic surgery, cosmetic outcome should be an important consideration. Goebel and Goldberg³³ reported the study on cosmetic appeal of different incision types using myomectomy as the model. In their study, 100 women between the ages of 20 years and 40 years were shown four color photographs of a female abdomen with incision sites marked for Pfannenstiel, minilaparotomy, conventional laparoscopy, and robotic-assisted laparoscopy. The women were asked to rank the photographs on cosmetic appeal alone. An additional photograph depicting single-port laparoscopy was then added, and patients were asked to rank the photographs again. Seventy-four percent of participants chose minilaparotomy as the most cosmetically appealing incision type when presented with the first set of photographs, whereas 26% preferred the appearance of conventional laparoscopy. When the single-port photograph was included, 64% ranked it the most appealing, 31% still preferred minilaparotomy, and 5% chose conventional laparoscopy as their first choice. They concluded that patients in this study strongly preferred the appearance of minilaparotomy and single-port incisions over full Pfannenstiel or robotic incisions.

Future trends

Closely related to SILS, NOTES, which completely eliminates abdominal incisions penetrating into the abdominal cavity, is an emerging and experimental alternative to conventional surgery. This procedure combines endoscopic and laparoscopic techniques to diagnose and treat abdominal pathologies. In 2007, the experiences of transvaginal endoscopic cholecystectomy in a human being were published.^{34–36} Subsequently, similar procedures were

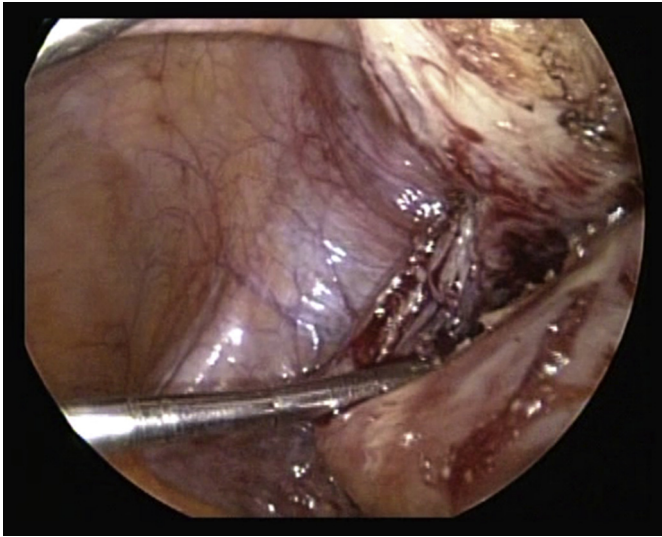


Figure 9. Intraoperative image of single-incision culdolaparoscopic myomectomy with transvaginal use of the EndoCAMEleon.

reported. Thanks to the development of a flexible endoscope and new transvaginal instruments, interest has been generated in culdoscopy and transvaginal surgery. The applications of NOTES in gynecology have been published for diagnostic,³⁷ adnexal procedures,^{38–40} hysterectomy,^{41–43} and myomectomy.⁴⁴ Several key areas of NOTES require further investigation. The author⁴⁰ reported hybrid transvaginal and transumbilical laparoendoscopic adnexal surgery. One of the most exciting areas is the use of a culdoscope to perform surgery through a single umbilical incision. With transvaginal use of the EndoCAMEleon, single-incision culdolaparoscopic myomectomy can be performed (Figure 9).

Conclusion

Although the evidence supporting a real advantage of SILS over conventional laparoscopy in postoperative complications, pain and hospital stay is lacking, SILS is still a feasible and safe treatment for most benign gynecologic disorders. Almost all benign gynecologic surgical procedures can be performed by a minimally invasive approach. Although single-incision laparoscopic myomectomy is considered a technically challenging procedure, this procedure has an obvious advantage of easier and safer retrieval of removed myomas via a larger incision compared with conventional laparoscopic myomectomy. The availability of new specific access ports and instruments has led to increased use in clinical practice and stirred further development. The integration of SILS, robotics and NOTES will certainly contribute to a wider application of this approach.

References

- Wang PH, Lee WL, Cheng MH, Yen MS, Chao KC, Chao HT. Use of a gonadotropin-releasing hormone agonist to manage perimenopausal women with symptomatic uterine myomas. *Taiwan J Obstet Gynecol.* 2009;48:133–137.
- Yoshiki N, Okawa T, Kubota T. Single-incision laparoscopic myomectomy with intracorporeal suturing. *Fertil Steril.* 2011;95:2426–2428.
- Bouwsma EV, Hesley GK, Woodrum DA, et al. Comparing focused ultrasound and uterine artery embolization for uterine fibroids—rationale and design of the Fibroid Interventions: Reducing Symptoms Today and Tomorrow (FIRSTT) trial. *Fertil Steril.* 2011;96:704–710.
- Lee WL, Liu WM, Cheng MH, Chao HT, Fuh JL, Wang PH. Uterine vascular occlusion in management of leiomyomas: laparoscopy vs laparotomy. *J Minim Invasive Gynecol.* 2009;16:562–568.

- Lee WL, Liu WM, Fuh JL, Tsai YC, Shih CC, Wang PH. Use of uterine vessel occlusion in the management of uterine myomas: two different approaches. *Fertil Steril.* 2010;94:1875–1881.
- Garza Leal JG, Hernandez Leon I, Castillo Saenz L, Lee BB. Laparoscopic ultrasound-guided radiofrequency volumetric thermal ablation of symptomatic uterine leiomyomas: feasibility study using the Halt 2000 Ablation System. *J Minim Invasive Gynecol.* 2011;18:364–371.
- Pritts EA, Parker WH, Olive DL. Fibroids and infertility: an update systematic review of the evidence. *Fertil Steril.* 2009;91:1215–1223.
- Herrmann A, De Wilde RL. Laparoscopic myomectomy—the gold standard. *Gynecol Minim Invasive Ther.* 2014;3:31–38.
- Lim MC, Kim TJ, Kang S, Bae DS, Park SY, Seo SS. Embryonic natural orifice transumbilical endoscopic surgery (E-NOTES) for adnexal tumors. *Surg Endosc.* 2009;23:2445–2449.
- Fader AN, Escobar PF. Laparoendoscopic single-site surgery (LESS) in gynecologic oncology: technique and initial report. *Gynecol Oncol.* 2009;114:157–161.
- Lee YY, Kim TJ, Kim CJ, et al. Single-port access laparoscopic-assisted vaginal hysterectomy: a novel method with a wound retractor and a glove. *J Minim Invasive Gynecol.* 2009;16:450–453.
- Fagotti A, Fanfani F, Marocco F, Rossitto C, Gallotta V, Scambia G. Laparoendoscopic single-site surgery (LESS) for ovarian cyst enucleation: report of first 3 cases. *Fertil Steril.* 2009;92:1168e13–16.
- Escobar PF, Fader AN, Paraiso MF, Kaouk JH, Falcone T. Robotic-assisted laparoendoscopic single-site surgery in gynecology: initial report and technique. *J Minim Invasive Gynecol.* 2009;16:589–591.
- Langebrekke A, Qvigstad E. Total laparoscopic hysterectomy with single-port access without vaginal surgery. *J Minim Invasive Gynecol.* 2009;16:609–611.
- Kim TJ, Lee YY, Kim MJ, et al. Single port access laparoscopic adnexal surgery. *J Minim Invasive Gynecol.* 2009;16:612–615.
- Wheless Jr CR, Thompson BH. Laparoscopic sterilization. Review of 3600 cases. *Obstet Gynecol.* 1973;42:751–758.
- Lee M, Kim SW, Nam EJ, Yim GW, Kim S, Kim YT. Single-port laparoscopic surgery is applicable to most gynecologic surgery: a single surgeon's experience. *Surg Endosc.* 2012;26:1318–1324.
- Einarsson JJ. Single-incision laparoscopic myomectomy. *J Minim Invasive Gynecol.* 2010;17:371–373.
- Jackson TR, Einarsson JJ. Single-incision laparoscopic myomectomy. *J Minim Access Surg.* 2011;7:83–86.
- Mereu L, Angioni S, Pontis A, Carri G, Mencaglia L. Single port access laparoscopic myomectomy with X-Cone. *Gynecol Surg.* 2011;8:337–340.
- Song T, Kim TJ, Kim WY, Lee SH. Comparison of barbed suture versus traditional suture in laparoendoscopic single-site myomectomy. *Eur J Obstet Gynecol Reprod Biol.* 2015;185:99–102.
- Kim YW, Park BJ, Ro DY, Kim TE. Single-port laparoscopic myomectomy using a new single-port transumbilical morcellation system: initial clinical study. *J Minim Invasive Gynecol.* 2010;17:587–592.
- Lee JH, Choi JS, Jeon SW, Son CE, Lee SJ, Lee YS. Single-port laparoscopic myomectomy using transumbilical GelPort access. *Eur J Obstet Gynecol Reprod Biol.* 2010;153:81–84.
- Kim JY, Kim KH, Choi JS, Lee JH. A prospective matched case-control study of laparoendoscopic single-site vs conventional laparoscopic myomectomy. *J Minim Invasive Gynecol.* 2014;21:1036–1040.
- Lim MC, Song YJ, Seo SS, Ryu J, Park SY. Embryonic-natural orifice transumbilical endoscopic surgery for myomectomy with traction of multidirectional sutures: a new surgical approach. *J Laparoendosc Adv Surg Tech A.* 2011;21:35–37.
- Choi CH, Kim TH, Kim SH, et al. Surgical outcomes of a new approach to laparoscopic myomectomy: single-port and modified suture technique. *J Minim Invasive Gynecol.* 2014;21:580–585.
- Yoon A, Kim TJ, Lee YY, et al. Laparoendoscopic single-site (LESS) myomectomy: characteristics of the appropriate myoma. *Eur J Obstet Gynecol Reprod Biol.* 2014;175:58–61.
- Kim SK, Lee JH, Lee JR, Suh CS, Kim SH. Laparoendoscopic single-site myomectomy versus conventional laparoscopic myomectomy: a comparison of surgical outcomes. *J Minim Invasive Gynecol.* 2014;21:775–781.
- Lee JR, Lee JH, Kim JY, Chang HJ, Suh CS, Kim SH. Single port laparoscopic myomectomy with intracorporeal suture-tying and transumbilical morcellation. *Eur J Obstet Gynecol Reprod Biol.* 2014;181:200–204.
- Lee HJ, Kim JY, Kim SK, Lee JR, Suh CS, Kim SH. Learning curve analysis and surgical outcomes of single-port laparoscopic myomectomy. *J Minim Invasive Gynecol.* 2015;22:607–611.
- Han CM, Lee CL, Su H, Wu PJ, Wang CJ, Yen CF. Single-port laparoscopic myomectomy: initial operative experience and comparative outcome. *Arch Gynecol Obstet.* 2013;287:295–300.
- Ramesh B, Vidyashankar M, Bharathi B. Single incision laparoscopic myomectomy. *J Gynecol Endosc Surg.* 2011;2:61–63.
- Goebel K, Goldberg JM. Women's preference of cosmetic results after gynecologic surgery. *J Minim Invasive Gynecol.* 2014;21:64–67.
- Zorron R, Filgueiras M, Maggioni LC, Pombo L, Lopes Carvalho G, Lacerda Oliveira A. NOTES. Transvaginal cholecystectomy: report of the first case. *Surg Innov.* 2007;14:279–283.
- Bessler M, Stevens PD, Milone L, Parikh M, Fowler D. Transvaginal laparoscopically assisted endoscopic cholecystectomy: a hybrid approach to natural orifice surgery. *Gastrointest Endosc.* 2007;66:1243–1245.

36. Marescaux J, Dallemagne B, Perretta S, Wattiez A, Mutter D, Coumaros D. Surgery without scars: report of transluminal cholecystectomy in a human being. *Arch Surg*. 2007;142:823–826.
37. Hackethal A, Ionesi-Pasacica J, Eskef K, Oehmke F, Muenstedt K, Tinneberg HR. Transvaginal NOTES with semi-rigid and rigid endoscopes that allow adjustable viewing angles. *Arch Gynecol Obstet*. 2011;283:131–132.
38. Lee CL, Wu KY, Su H, Ueng SH, Yen CF. Transvaginal natural-orifice transluminal endoscopic surgery (NOTES) in adnexal procedures. *J Minim Invasive Gynecol*. 2012;19:509–513.
39. Ahn KH, Song JY, Kim SH, Lee KW, Kim T. Transvaginal single-port natural orifice transluminal endoscopic surgery for benign uterine adnexal pathologies. *J Minim Invasive Gynecol*. 2012;19:631–635.
40. Yoshiki N, Okawa T, Kubota T. Hybrid transvaginal and transumbilical laparoendoscopic adnexal surgery. *J Laparoendosc Adv Surg Tech A*. 2012;22:992–995.
41. Su H, Yen CF, Wu KY, Han CM, Lee CL. Hysterectomy via transvaginal natural orifice transluminal endoscopic surgery (NOTES): feasibility of an innovative approach. *Taiwan J Obstet Gynecol*. 2012;51:217–221.
42. Yang YS, Kim SY, Hur MH, Oh KY. Natural orifice transluminal endoscopic surgery-assisted versus single-port laparoscopic-assisted vaginal hysterectomy: a case-matched study. *J Minim Invasive Gynecol*. 2014;21:624–631.
43. Lee CL, Wu KY, Su H, Wu PJ, Han CM, Yen CF. Hysterectomy by transvaginal natural orifice transluminal endoscopic surgery (NOTES): a series of 137 patients. *J Minim Invasive Gynecol*. 2014;21:818–824.
44. Lee CL, Huang CY, Wu KY, Hu YF, Yen CF, Han CM. Natural orifice transvaginal endoscopic surgery myomectomy: an innovative approach to myomectomy. *Gynecol Minim Invasive Ther*. 2014;3:127–130.