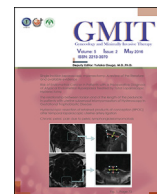



Contents lists available at ScienceDirect

Gynecology and Minimally Invasive Therapy

journal homepage: www.e-gmit.com

Case report

Chronic pelvic pain due to pelvic lymphangioleiomyomatosis: A case report



Tetsu Wakimoto^a, Tateki Tsutsui^{a, b, *}, Mahiru Kawano^a, Namhyo Kim^{a, c},
Akihiro Moriyama^c, Tadashi Kimura^a

^a Department of Obstetrics and Gynecology, Osaka University Graduate School of Medicine, Osaka, Japan

^b Department of Obstetrics and Gynecology, Japan Community Healthcare Organization Osaka Hospital, Osaka, Japan

^c Department of Obstetrics and Gynecology, Saiseikai Nakatsu Hospital, Osaka, Japan

ARTICLE INFO

Article history:

Received 14 November 2015

Received in revised form

11 February 2016

Accepted 23 February 2016

Available online 4 April 2016

Keywords:

lymphangioleiomyomatosis

pelvic pain

retroperitoneum

ABSTRACT

Lymphangioleiomyomatosis (LAM), a rare multisystem disease affecting mainly young women, is characterized by an abnormal proliferation of smooth muscle-like cells in the lungs. We report a case of endometriosis with chronic pelvic pain due to pelvic LAM. A 41-year-old gravida 1, para 1 woman had been experiencing intermittent left pelvic pain for several years. She also complained of dyspnea on effort 2 years previously, and was diagnosed with pulmonary LAM. Abdominal magnetic resonance imaging showed a right ovarian endometriotic cyst and a left pelvic mass. She was referred to our hospital for the treatment of pelvic pain; she underwent laparoscopic cystectomy of the right ovarian endometriotic cyst. Her left pelvic cyst was found in the retroperitoneal space, and biopsy confirmed the diagnosis of LAM. Therefore, we suggest that LAM localized in the pelvis should be considered when a patient with pulmonary LAM presents with pelvic pain or abdominal distention.

Copyright © 2016, The Asia-Pacific Association for Gynecologic Endoscopy and Minimally Invasive Therapy. Published by Elsevier Taiwan LLC. This is an open access article under the CC BY-NC-ND license (<http://creativecommons.org/licenses/by-nc-nd/4.0/>).

Introduction

Lymphangioleiomyomatosis (LAM) is very rare disease that mainly affects women of reproductive age. The pathological feature of LAM is an abnormal proliferation of smooth muscle-like cells (LAM cells) mainly in the wall of airways, venules, and lymphatic vessels in the lungs. The proliferation of these cells causes gradual obstruction of small airways, frequently resulting in respiratory failure and death. Patients with pulmonary LAM have mainly respiratory symptoms such as dyspnea on effort, chest pain, cough, and sputum with or without blood. However, LAM sometimes affects extrapulmonary lesions such as retroperitoneal lymphatic tumors (lymphangioleiomyomas) and renal angiomyolipomas, causing abdominal distention, abdominal pain, lymphedema of the lower extremities, and hematuria. Here we report a difficult-to-

diagnose case of endometriosis in a patient who complained of chronic pelvic pain due to pelvic LAM.

Case report

A 41-year-old gravida 1, para 1 woman was referred to our hospital for the treatment of pelvic pain. She had presented with complaints of dyspnea on effort 2 years previously, and had received a diagnosis of pulmonary LAM and bilateral renal angiomyolipomas from her physician. She also had been experiencing left pelvic pain for several years, which gradually worsened. The visual analogue scale score of her pelvic pain was 6–10/10. Magnetic resonance imaging revealed an endometriotic cyst in her right ovary and a left ovarian cyst or retroperitoneal cyst in her left pelvic cavity. Her previous gynecologist thought that surgery was needed; however, surgery was not possible because of the patient's low respiratory function. Her respiratory function test revealed severe pulmonary obstructive dysfunction (percentage vital capacity (% VC), 125%; percent predicted forced expiratory volume in one second (FEV1.0%), 29.1%). Chest radiography showed diffuse reticular shadows in both lungs, and her breathlessness was categorized as Grade 2 in the Hugh–Jones classification. She also had multiple

Conflicts of interest: The authors have no conflicts of interest relevant to this article.

* Corresponding author. Department of Obstetrics and Gynecology, Japan Community Healthcare Organization Osaka Hospital, 4-2-78, Fukushima, Fukushima Ward, Osaka 553-0003, Japan.

E-mail address: tatekitsu@icloud.com (T. Tsutsui).

<http://dx.doi.org/10.1016/j.jgmit.2016.02.003>

2213-3070/Copyright © 2016, The Asia-Pacific Association for Gynecologic Endoscopy and Minimally Invasive Therapy. Published by Elsevier Taiwan LLC. This is an open access article under the CC BY-NC-ND license (<http://creativecommons.org/licenses/by-nc-nd/4.0/>).

diffuse cystic lesions in both lungs on chest computed tomography. Transvaginal ultrasonography revealed that the right ovarian cyst had a mosaic pattern and was enlarged to 5 cm in diameter, and a hypochoic cystic lesion that had a small solid portion on the inside in her left pelvis. Although the cancer antigen 125 level increased to 85 IU/mL, other tumor makers were within the normal range in her blood test. On magnetic resonance imaging the right adnexal cyst was 6 cm in diameter with high-signal intensity on both T1- and T2-weighted imaging, and was diagnosed as an endometriotic cyst. The cystic mass in the left pelvis was 5 cm in diameter with low-signal intensity on T1- and high-signal intensity on T2-weighted imaging. Moreover, in the caudal side of the left adnexa, there was an area of high-signal intensity on T1-weighted imaging after gadolinium enhancement.

Considering all these findings, we tentatively diagnosed the left pelvic mass as LAM although we could not completely eliminate a possibility of left malignant ovarian tumor. We performed laparoscopic right salpingo-oophorectomy (RSO) using the usual approach. We could not find any obvious endometriotic lesion except for right ovarian endometriotic cyst in her pelvis. After RSO, we confirmed that the left ovary was normal and the cystic lesion was located in the left retroperitoneal space (Figures 1A and 1B). We separated the cyst from the left peritoneum, and finally opened the cyst. We confirmed the presence of ash-gray fluid content and mural nodule within the cyst, and took samples as much as possible for pathological analysis (Figures 1C and 1D). We could not completely remove the cyst wall from the retroperitoneal space because it was firmly attached to the surrounding tissue. The operation time was 2 hours 21 minutes and the total blood loss was 30 mL. The patient's postoperative course was uneventful, and she was discharged from our hospital 4 days after the operation without any complications.

The cytology findings showed many spindle-shaped LAM cells in the fluid from the left retroperitoneal cyst (Figure 2A). Hematoxylin–eosin staining showed spindle-shaped cells without

atypia, and the proliferation of interstitial tissue (Figure 2B). In the immunohistochemical studies, the tumor was positive for anti-Ord2, anti-HMB45, anti- α SMA, anti-estrogen receptor, and anti-progesterone receptor antibodies (Figures 2C–2G). Finally, left retroperitoneal LAM complicated with right ovarian endometriotic cyst was diagnosed.

The patient received outpatient care for 6 months after surgery without any additional therapy. Her visual analogue scale score decreased to 0–1/10 after surgery. We suggested left salpingo-oophorectomy to the patient because LAM might subside after bilateral oophorectomy, but she did not accept it because she worried about postmenopausal symptoms.

Discussion

LAM is very rare multisystem disease that affects mainly women of childbearing age. Its usual presentation is dyspnea, pneumothorax, chylous pleural effusion, and hemoptysis. The prognosis is poor because of progressive obstructive respiratory dysfunction. The estimated prevalence rate of LAM in Japan is 1.2–2.3/1,000,000 persons.¹

LAM is categorized into two groups: (1) LAM in conjunction with tuberous sclerosis complex (TSC); and (2) LAM without evidence of other diseases (sporadic LAM). In 1994 the genetic background of LAM was discovered to be somatic or germline mutations of the tumor suppressor genes *TSC1* and *TSC2*.² It is thought that LAM patients with TSC have one germline mutation (predominantly in *TSC2*) and one acquired mutation, and that sporadic LAM develops in the presence of two acquired mutations in *TSC* genes (again predominantly in *TSC2*) in somatic cells. In the lungs, multiple cystic lesions form because of the proliferation of LAM cells that have TSC gene abnormality. LAM forms not only pulmonary lesions but also extrapulmonary lesions. The common extrapulmonary abnormalities are angiomyolipomas, abdominal effusion containing LAM cells, and enlargement of the mediastinal and

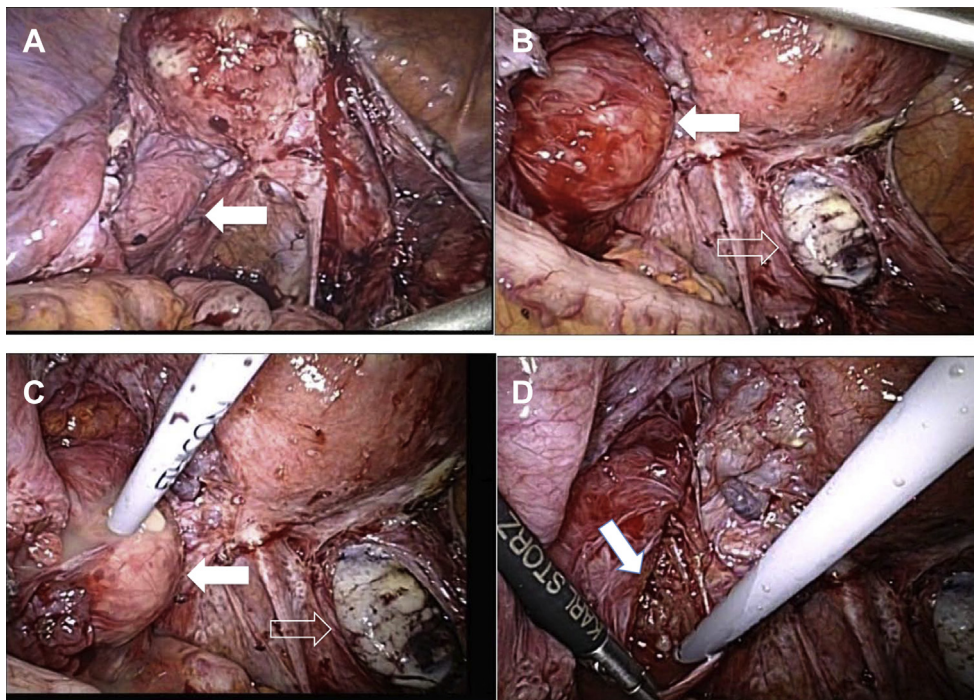


Figure 1. Laparoscopic operation findings. Pelvic lymphangioleiomyomatosis located in the left retroperitoneal space (closed arrow) and the removed right endometriotic cyst wall (open arrow). Cystic mass before (A, B, C) and after (D) aspirating its content.

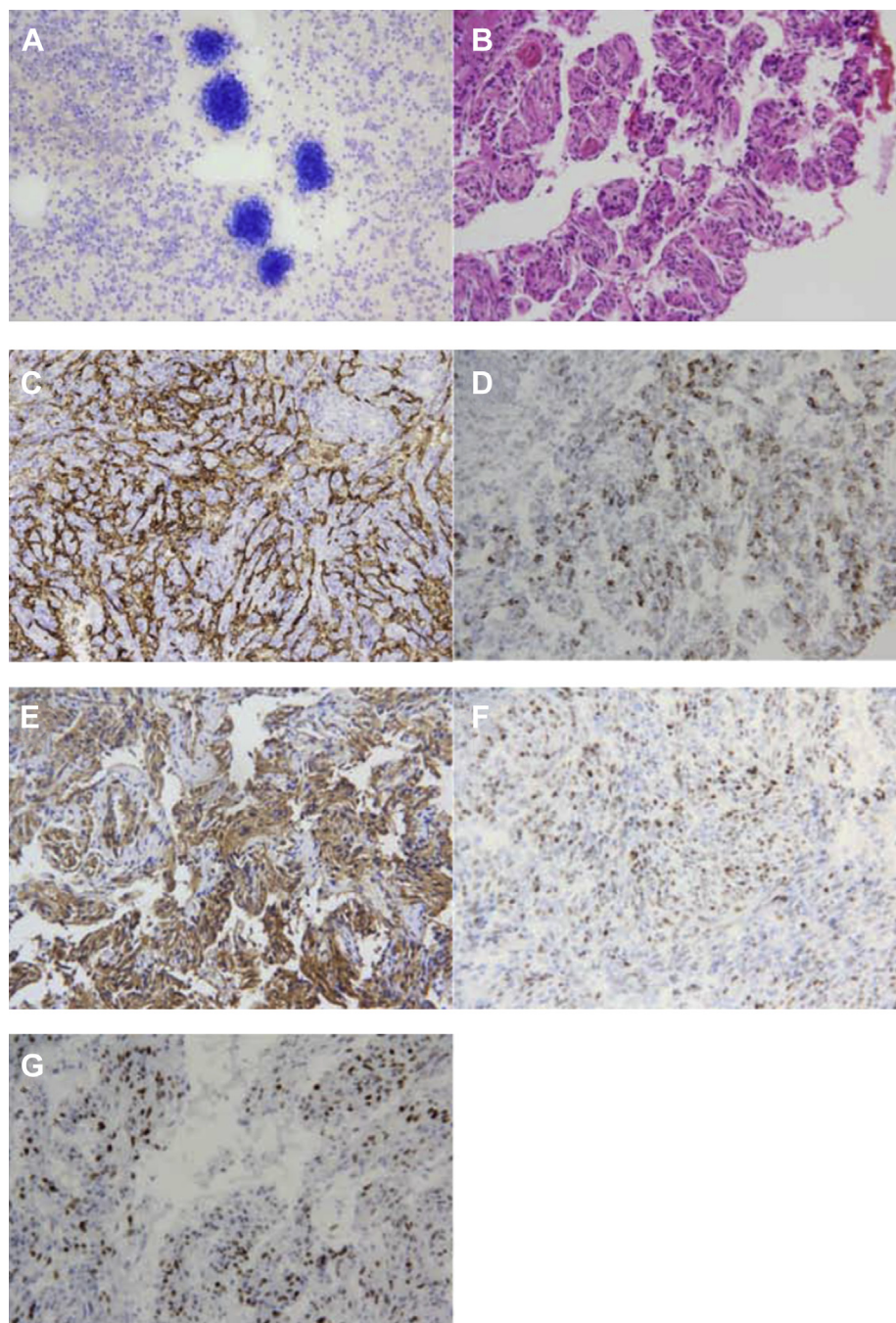


Figure 2. Pathological findings ($\times 400$). (A) Cytology: lymphangioleiomyomatosis cells in the cyst. (B) Hematoxylin–eosin staining. (C) Org-D2 staining. (D) Anti-HMB45 antibody. (E) Anti- α SMA antibody. (F) Anti-estrogen receptor antibody. (G) Antiprogesterone receptor antibody.

retroperitoneal lymph nodes around the abdominal aorta and pelvis.³ Evidence has shown that LAM may be influenced by female sex hormones. Some reports mentioned that LAM worsened during pregnancy and that bilateral oophorectomy improved respiratory function.^{4,5}

Pathological studies are important for the diagnosis of LAM. LAM cells can be classified into two types: smaller spindle-shaped cells and larger epithelioid cells with abundant cytoplasm.⁶ Immunohistochemical analysis is also important. We performed immunohistochemical staining of LAM cells with anti-HMB45, anti- α SMA, anti-estrogen receptor, and antiprogesterone receptor antibodies. The positive rate of these staining tests is 80% for anti-

HMB45 antibody, 98% for anti- α SMA antibody, 53% for anti-estrogen receptor antibody, and 68% for antiprogesterone receptor antibody, respectively.

Recently, sirolimus (rapamycin) has drawn attention as a possible therapeutic agent for LAM. LAM is associated with an inappropriate activation of mammalian target of rapamycin (mTOR) signaling, and sirolimus inactivates mTOR, consequently inhibiting cell proliferation.⁷

Pelvic LAM before the appearance of respiratory symptoms was reported previously.⁸ Preoperative diagnosis is thought to be more difficult in these cases. In most of the patients with extrapulmonary lesion, the diagnosis of respiratory lesion was made within 1 year or

2 years after the diagnosis of the extrapulmonary lesion.⁹ Numata et al¹⁰ reported a case of LAM complicated with a retroperitoneal tumor composed of LAM cells. The patient did not complain of pelvic pain, which suggests that pelvic LAM may not always cause lower abdominal pain.

In our case it was difficult to determine whether the cause of pelvic pain was caused by endometriosis or retroperitoneal LAM before surgery.^{11,12} The pain of this patient was left lower abdomen ipsilateral to the LAM lesion, therefore, we speculated that LAM in the retroperitoneal lesion swelled out and irritated the peritoneum, which should cause her chronic pelvic pain.

Taking all the findings together, we concluded that her chronic pelvic pain was due to left retroperitoneal LAM, not endometriosis. Pelvic LAM should be considered as a differential diagnosis when patients present with pelvic pain coexistent with a pulmonary LAM lesion. We suggest that LAM localized in the pelvis should be considered when a patient with pulmonary LAM presents with pelvic pain or abdominal distention. Laparoscopic lymph node biopsy is a valuable tool in solving such a diagnostic dilemma.

References

- Hayashida M, Seyama K, Inoue Y, Fujimoto K, Kubo K. Respiratory Failure Research Group of the Japanese Ministry of Health, Labor, and Welfare. The epidemiology of lymphangioleiomyomatosis in Japan: a nationwide cross-sectional study of presenting features and prognostic factors. *Respirology*. 2007;12:523–530.
- Green AJ, Smith M, Yates JR. Loss of heterozygosity on chromosome 16p13.3 in hamartomas from tuberous sclerosis patients. *Nat Genet*. 1994;6:193–196.
- Hayashi T, Kumasaka T, Mitani K, et al. Prevalence of uterine and adnexal involvement in pulmonary lymphangioleiomyomatosis: a clinicopathologic study of 10 patients. *Am J Surg Pathol*. 2011;35:1776–1785.
- Brunelli A, Catalini G, Fianchini A. Pregnancy exacerbating unsuspected mediastinal lymphangioleiomyomatosis and chylothorax. *Int J Gynecol Obstet*. 1996;52:289–290.
- Kitzsteiner KA, Mallen RG. Pulmonary lymphangioleiomyomatosis: treatment with castration. *Cancer*. 1980;46:2248–2249.
- Ferrans VJ, Yu ZX, Nelson WK, et al. Lymphangioleiomyomatosis (LAM): a review of clinical and morphological features. *J Nippon Med Sch*. 2000;67:311–329.
- Casanova A, María Girón R, Acosta O, Barrón M, Valenzuela C, Ancochea J. Lymphangioleiomyomatosis treatment with sirolimus. *Arch Bronconeumol*. 2011;47:470–472.
- Yamashita S, Nakamura K, Shinozaki H, Minegishi T. Lymphangioleiomyomatosis suspected to be a gynecologic disease. *J Obstet Gynaecol Res*. 2011;37:267–269.
- Matsui K, Tatsuguchi A, Valencia J, et al. Extrapulmonary lymphangioleiomyomatosis (LAM): clinicopathologic features in 22 cases. *Hum Pathol*. 2000;31:1242–1248.
- Numata T, Araya J, Mikami J, et al. A case of pulmonary lymphangioleiomyomatosis complicated with uterine and retroperitoneal tumors. *Respir Med Case Rep*. 2015;15:71–76.
- Wu MH, Hsiao KY, Tsai SJ. Endometriosis and possible inflammation markers. *Gynecol Minim Invasive Ther*. 2015;4:61–67.
- Wee-Stekly WW, Kew CC, Chern BS. Endometriosis: a review of the diagnosis and pain management. *Gynecol Minim Invasive Ther*. 2015;4:106–109.