

## Original article

## Preoperative dienogest to improve the surgical field of view in resectoscopic surgery



Takehiko Tsuchiya\*, Yukiko Katagiri, Toshimitsu Maemura, Eijiro Hayata, Yusuke Fukuda, Mamoru Kitamura, Mineto Morita

Department of Obstetrics and Gynecology, Toho University Omori Medical Center, Tokyo, Japan

## ARTICLE INFO

## Article history:

Received 12 November 2014

Received in revised form

21 January 2015

Accepted 21 January 2015

Available online 21 May 2015

## Keywords:

dienogest

resectoscopic surgery

submucous myoma

## ABSTRACT

**Introduction:** Resectoscopic surgery requires high technological skill to perform the procedure in a limited field of vision. With the preoperative administration of dienogest, a good surgical field of vision can be secured. The lesion and the normal endometrium are easily distinguished, and therefore the removal of normal endometrium can be minimized.

**Methods:** Preoperative dienogest was administered to 28 patients with submucosal myomas, 18 patients with endometrial polyps, and one patient with Asherman's syndrome. The patients began taking oral dienogest (2 mg/d) on Day 5 of preoperative menstruation until the day before surgery. Use of dienogest before resectoscopic surgery was approved by the Institutional Review Board of Toho Medical Center Oomori Hospital (Tokyo, Japan; approval number 24-185).

**Results:** The duration of oral dienogest treatment was 14–72 days in patients with submucosal myoma and 18–85 days in patients with endometrial polyps. Slight thickening of the endometrium occurred in patients who were administered dienogest for 14 days. However, a thin endometrium occurred in patients who took the drug for 28 days or longer. Submucosal myomas and endometrial polyps were easily distinguished from the normal myometrium. A sufficient intrauterine surgical field was secured to minimize endometrial damage in all patients.

**Conclusion:** We found that preoperative dienogest effectively minimized endometrial damage in resectoscopic surgery by thinning the endometrium and clearing the surgical field of vision.

Copyright © 2015, The Asia-Pacific Association for Gynecologic Endoscopy and Minimally Invasive Therapy. Published by Elsevier Taiwan LLC. All rights reserved.

## Introduction

Resectoscopic surgery requires a surgeon to perform the procedure in a limited field of vision. A thin endometrium is preferred because a thick endometrium decreases the surgical field of vision.<sup>1</sup> Surgeries used to be scheduled immediately after menstruation, when the endometrium is thin. However, scheduling a surgery immediately after menstruation is usually difficult because the timing of patient admission and the availability of the operation room need to coincide. In some patients, the endometrium is thick or it is difficult to secure a good surgical field of vision because the

patients are still menstruating, even after the surgery. By using preoperative dienogest, surgery scheduling is not affected by the patient's menstrual cycle, a good surgical field of vision is secured, the lesion and the normal endometrium are easily distinguished, and the removal of normal endometrium can be minimized. We report the effectiveness of preoperative dienogest, which inhibits endometrial proliferation, in patients with submucosal myomas or endometrial polyps who are scheduled for resectoscopic surgery.

## Materials and methods

This study included patients clinically diagnosed as having endometriosis, based on dysmenorrhea or hypermenorrhea, or patients who had documented endometriosis and were scheduled for laparoscopic surgery and subsequently diagnosed as having submucosal myoma or endometrial polyp (based on transvaginal sonography or MRI) and wished to undergo resectoscopic surgery. Preoperative dienogest was administered to 28 patients with

Conflicts of interest: The authors have no financial conflicts of interest to report.

\* Corresponding author. Department of Obstetrics and Gynecology, Toho University Omori Medical Center, 6-11-1 Omori-Nishi, Ota-ku, Tokyo, 143-8541, Japan.

E-mail address: [takehiko-t@med.toho-u.ac.jp](mailto:takehiko-t@med.toho-u.ac.jp) (T. Tsuchiya).

submucosal myomas, 18 patients with endometrial polyps, and one patient with Asherman's syndrome. They were scheduled for surgery and able to receive inpatient treatment. They gave informed consent in advance. Oral administration of dienogest (2 mg/d) was started on Day 5 of preoperative menstruation until the day before surgery. Two laminaria (size S) were inserted the night before surgery as a preoperative treatment. A monopolar or bipolar resectoscope (Karl Storz Endoskope; Karl Storz Endoskope, Tuttingen, Germany) was used for the resectoscopic surgery in patients under general anesthesia. As the perfusate, D-sorbitol was used with the monopolar resectoscope and isotonic sodium chloride solution was used with the bipolar resectoscope. Use of dienogest before resectoscopic surgery was approved by the Institutional Review Board of the Toho Medical Center Oomori Hospital (Tokyo, Japan; approval number 24-185).

## Results

The duration of oral administration dienogest treatment was 14–72 days in patients with submucosal myomas, 18–85 days in patients with endometrial polyps, and 12 days in patients with Asherman's syndrome. Resectoscopic myomectomy lasted 8–102 minutes, resectoscopic polypectomy lasted 6–27 minutes, and resectoscopic adhesiotomy lasted for 12 minutes. The amount of perfusate used was 2000–18,000 mL in resectoscopic myomectomy, 1200–4500 mL in resectoscopic polypectomy, and 3000 mL in resectoscopic adhesiotomy. A slight thickening of the endometrium only occurred with the administration of dienogest for 14 days. However, patients who had taken the medication for at least 28 days had a thin endometrium. Submucosal myomas or endometrial polyps were clearly distinguished from the normal myometrium. In all patients, a sufficient intrauterine surgical field was secured to minimize endometrial damage. No endometrium was found in patients treated with dienogest for approximately 56 days. Their intrauterine findings were comparable to those of patients treated preoperatively with a gonadotropin-releasing hormone agonist (GnRHa; Figures 1–4). No menopause-like symptoms were induced by dienogest before surgery. Nearly all patients had irregular vaginal bleeding associated with dienogest, although the blood was removed with the perfusate during resectoscopic surgery to prevent the obscuring of the surgical field. No patient had any serious complications such as water intoxication.

## Discussion

In 1978, the first resectoscopic surgery was reported by Neuwirth<sup>2</sup> who used a resectoscope for transurethral resection to remove a myoma. In 1986, Lin and colleagues<sup>3</sup> named the procedure “transcervical resection.” With the development of specific

surgical devices, transcervical resection is indicated for the treatment of various disorders such as submucosal myomas, endometrial polyps, deformity of the uterus, and intrauterine adhesions. Patients undergoing resectoscopic surgery at our hospital increased from eight patients in 2004 to 34 patients in 2012. Patients undergoing resectoscopic myomectomy have also increased significantly from two patients in 2005 to 25 patients in 2012. Our hospital surgical guidelines for submucosal myoma recommend performing laparoscopic myomectomy for myomas >3 cm in diameter and resectoscopic myomectomy for myomas <3 cm in diameter with a protrusion of >60%. In some patients with a submucosal myoma of <3 cm and little protrusion, excessive shrinkage of a submucosal myoma associated with GnRHa made it difficult to identify the lesion during surgery. Preoperative GnRHa adversely affected the surgical procedure in these patients. Therefore, as much as possible, we avoid using GnRHa for small submucosal myomas with little protrusion.

It is difficult to schedule a resectoscopic surgery based on the estimated cycle immediately after the last menstruation without preoperative medication because the expected onset of menstruation, the timing of the patient's admission, and the availability of the operation room at the hospital need to coincide. In some patients, menstruation did not start as expected after admission. Some patients have a thick endometrium in the luteal phase; in other patients, menstrual blood obscures the surgical field. The border between the myometrium and a submucosal myoma or endometrial polyp is difficult to identify in resectoscopic surgery of the uterus in patients with a thick endometrium. The surgery may damage the endometrium or cause serious complications such as uterine perforation. By thinning the endometrium, the lesion and the myometrium can be clearly distinguished and endometrial removal can be minimized. The future fertility of the patient may therefore be protected. Use of oral contraceptives before resectoscopic surgery to minimize the endometrial thickness has been previously reported.<sup>4–6</sup> However, use of oral contraceptives within 4 weeks of surgery is contraindicated in Japan. A GnRHa or dienogest containing no estrogen may be the only choice to adjust the surgical schedule. Dienogest is a fourth-generation progestin developed by Régine Sitruk-Ware in 2004.<sup>7</sup> Norethisterone is a first-generation progestin and has progesterone and androgenic actions. Compared to the first-generation progestin, the second-generation progestin levonorgestrel and the third-generation progestin desogestrel have an enhanced progesterone action on inhibiting ovulation. However, adverse reactions such as acne, hirsutism, and weight increase are more frequent because the androgen action is simultaneously enhanced. The fourth-generation progestin dienogest has no androgen action and has a 5.3-times higher progesterone action, compared to the first-generation progestin.<sup>8</sup>

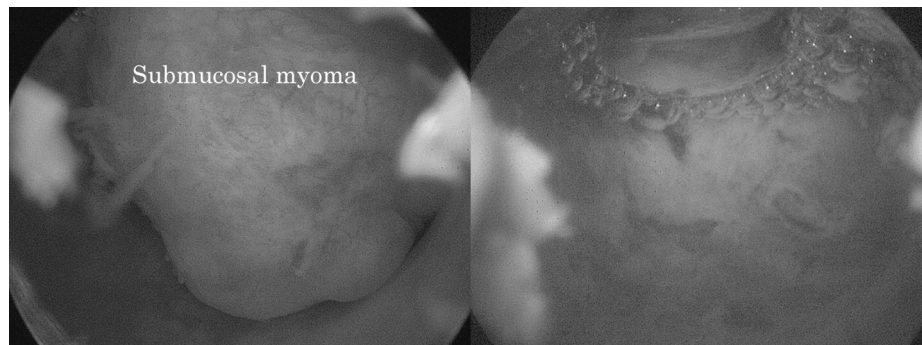
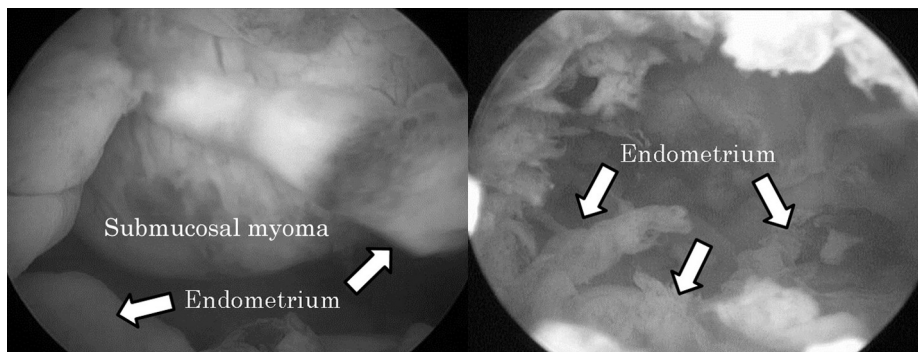
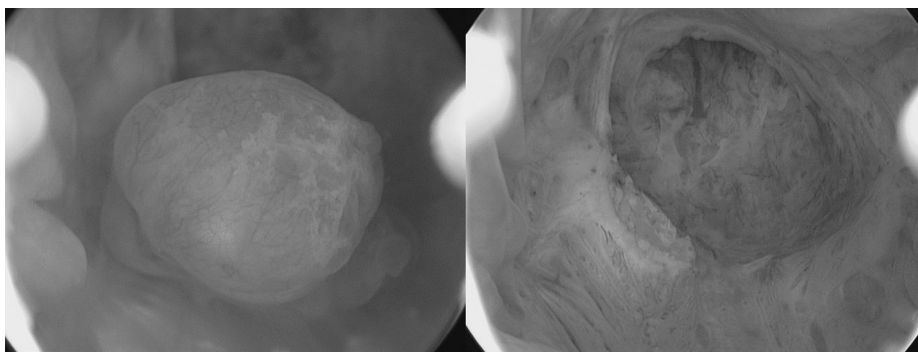


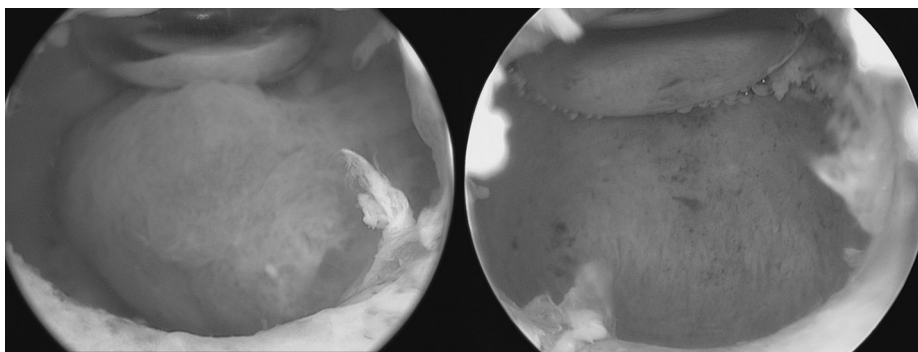
Figure 1. Dienogest administered for 21 days.



**Figure 2.** Dienogest administered for 14 days. The locus of the arrows indicates the thickened endometrium.



**Figure 3.** Dienogest administered for 18 days.



**Figure 4.** Dienogest administered for 56 days.

Nonclinical studies have reported the actions of dienogest on endometrial cells. Okada et al.<sup>9</sup> report in their *in vitro* study of cultured endometrial stromal cells that dienogest significantly inhibits cell proliferation at a concentration of  $>10^{-7}$  mol/L. Fu et al.<sup>10</sup> report similar results in their study of cultured endometrial stromal cells derived from ovarian endometriosis. Irahara et al.<sup>11</sup> reported in a clinical study, dienogest was administered to nine patients to evaluate the change in hormone levels, endometrial thickness, and follicular diameter from baseline to 16 weeks, based on transvaginal ultrasound and the endometrium thinned from 11.4 mm at baseline to 5.2 mm at 2 weeks after the administration of dienogest and never thickened again—it remained at 3.8–5.6 mm, which suggested that dienogest inhibits endometrial proliferation. Saito et al.<sup>12</sup> report the usefulness of dienogest administered 7–21 days before resectoscopic surgery.

There is no established timing or duration of preoperative dienogest treatment in patients undergoing resectoscopic surgery

and laparoscopy for endometriosis. In some of our patients who had undergone concurrent laparoscopy and resectoscopic surgery or had been diagnosed with endometriosis and scheduled for resectoscopic surgery, preoperative dienogest caused endometrial thinning, resulting in identification of endometrial lesion based on transvaginal ultrasound for the first time and underwent surgery thereafter. Therefore, our patients were treated for a longer time, compared to patients treated by Saito et al.<sup>12</sup> Endometrial thinning started ~14 days after starting dienogest, although the endometrium did not disappear with short-term treatment. It is more difficult to secure a surgical field of vision in resectoscopic myomectomy, which requires a higher level of surgical technique in comparison to resectoscopic polypectomy; therefore, patients with submucosal myomas may need to receive dienogest longer than patients with endometrial polyps. However, the treatment duration could be shorter than the duration in the previous case. After receiving dienogest, nearly all patients had irregular vaginal

bleeding before undergoing resectoscopy. According to Momoeda and colleagues,<sup>13</sup> irregular vaginal bleeding is most frequent after 5–8 weeks of dienogest treatment. Patients should therefore be thoroughly informed of the likelihood of irregular vaginal bleeding associated with dienogest. Irregular vaginal bleeding did not hinder the surgical procedure because the blood was rinsed away by the perfusate in the intrauterine cavity to clear the surgical field.

A submucosal myoma reduces by administering GnRHa, but may cause excessive bleeding. In addition, in the submucosal myoma low projecting rate make us stop to use GnRHa, without reduction of the protruding rate due to reduction of myoma by administering the dienogest, effective way of endometrium to thinning considered. We found that preoperative dienogest effectively minimized endometrial damage in resectoscopic surgery by thinning the endometrium and clearing the surgical field of vision. We will further evaluate the timing and duration of treatment to establish preoperative dienogest therapy for resectoscopic surgery.

## References

1. Rai VS, Gillmer MD, Gray W. Is endometrial pre-treatment of value in improving the outcome of transcervical resection of the endometrium? *Hum Reprod.* 2000;15:1989–1992.
2. Neuwirth RS. A new technique for and additional experience with hysteroscopic resection of submucous fibroids. *Am J Obstet Gynecol.* 1978;131:91–94.
3. Lin BL, Miyamoto N, Aoki R, Iwata Y, Iizuka R. Transcervical resection of submucous myoma. *Nihon Sanka Fujinka Gakkai Zasshi.* 1986;38:1647–1652.
4. Grow DR, Iromloo K. Oral contraceptives maintain a very thin endometrium before operative hysteroscopy. *Fertil Steril.* 2006;85:204–207.
5. Cicinelli E, Pinto V, Quattromini P, et al. Endometrial preparation with estradiol plus dienogest (Qlaira) for office hysteroscopic polypectomy: randomized pilot study. *J Minim Invasive Gynecol.* 2012;19:356–359.
6. Bifulco G, Di Spiezo Sardo A, De Rosa N, et al. The use of an oral contraceptive containing estradiol valerate and dienogest before office operative hysteroscopy: a feasibility study. *Gynecol Endocrinol.* 2012;28:949–955.
7. Sitruk-Ware R. New progestogens: a review of their effects in perimenopausal and postmenopausal women. *Drugs Aging.* 2004;21:865–883.
8. Momoeda M. Development of progestin and endometriosis treatment. *Progress in Medicine.* 2008;28:135–145 [In Japanese].
9. Okada H, Nakajima T, Yoshimura T, Yasuda K, Kanzaki H. The inhibitory effect of dienogest, a synthetic steroid, on the growth of human endometrial stromal cells *in vitro*. *Mol Hum Reprod.* 2001;7:341–347.
10. Fu L, Osuga Y, Morimoto C, et al. Dienogest inhibits BrdU uptake with G0/G1 arrest in cultured endometriotic stromal cells. *Fertil Steril.* 2008;89:1344–1347.
11. Irahara M, Harada T, Momoeda M, Tamaki Y. Hormonal and histological study on irregular genital bleeding in patients with endometriosis during treatment with dienogest, a novel progestational therapeutic agent. *Reprod Med Biol.* 2007;6:223–228.
12. Saito J, Nishigaya Y, Morikawa K, et al. A change of an endometrial cavity and hysteroscopy of Dienogest administration. *Nippon Endometriosis Gakkai.* 2010;31:177–179 [In Japanese].
13. Momoeda M, Harada T, Terakawa N, et al. Long-term use of dienogest for the treatment of endometriosis. *J Obstet Gynaecol Res.* 2009;35:1069–1076.