



Review article

Single incision laparoscopic surgery in gynecology: Evolution, current trends, and future perspectives

Bernard Su Min Chern^{a,*}, Smita Lakhotia^a, Chong Kiat Khoo^a, Anthony Yew Ming Siow^b^a KK Women's and Children's Hospital, Singapore^b Parkway Gynaecology Screening and Treatment Centre, Singapore

ARTICLE INFO

Article history:

Received 7 October 2011

Received in revised form

1 August 2012

Accepted 13 August 2012

Available online 10 October 2012

Keywords:

Conventional laparoscopic surgery
 Laparoendoscopic single-site surgery (LESS)
 Single-incision laparoscopic surgery (SILS)
 Single port

ABSTRACT

Minimally invasive surgery has become the standard of care for different procedures in various subspecialties. Single-incision laparoscopic surgery (SILS) is a rapidly developing field that may mark the new frontier in laparoscopy. The ongoing and continuous efforts to decrease morbidity and improve cosmesis from laparoscopic surgery has led to minimization in number and size of ports required for these procedures. SILS is laparoscopic surgery performed through a single, small skin incision 15–20 mm in size, usually hidden in the umbilicus. SILS is not a new endeavor, but recent advances in conventional laparoscopic techniques and instrumentation has made SILS more feasible and safer for patients. Within a short span of time there has been an increase in the number of studies and clinical reports depicting the use of SILS in gynecology. As this novel field moves forward, a review of its evolution and current status is requisite. The objective of this article is to review the contemporary literature on SILS in gynecology and the recent advances in techniques and instrumentation used in SILS. The ongoing refinement of surgical techniques and instrumentation has resulted in increasing use of SILS across many subspecialties. Recently published studies have proven the feasibility, safety, and reproducibility of SILS in various gynecologic procedures.

Copyright © 2012, The Asia-Pacific Association for Gynecologic Endoscopy and Minimally Invasive Therapy. Published by Elsevier Taiwan LLC. All rights reserved.

Introduction

Laparoscopic surgery has become the standard of care for many abdominal and pelvic surgeries. Several studies have proved that the laparoscopic approach to various benign and malignant conditions has resulted in decreased morbidity, shorter hospital stay, improved surgical outcomes, and improved quality of life when compared with conventional surgeries.^{1–3} Although laparoscopy has decreased the morbidity directly related to a surgical approach, each working port carries an inherent risk of bleeding, infection, concomitant organ damage, hernia formation, and decreased cosmetic outcome. Advances in surgical instrumentation and design have allowed minimal-access surgery to become even more minimal.^{4–6}

One of the more recent advances in the field of minimally invasive surgery is the increasing use of single-incision laparoscopic surgery (SILS) in various gynecologic procedures. SILS is an advanced

minimally invasive approach that allows laparoscopic surgery through a single incision in the umbilicus, the preexisting scar. By using a single multichannel port access system, SILS is an attempt to further enhance the cosmetic benefits of minimally invasive surgery while minimizing the potential risks and morbidity associated with multiple working ports. Data from the general surgery and urology literature have demonstrated technical feasibility and reproducibility of this technique when used for a variety of procedures, including cholecystectomy, appendectomy, nephrectomy, and hemicolectomy.^{7–12} These early reports from urology, surgery, and oncology studies designate that SILS is a potential surgical innovation that not only has aesthetic superiority, but also leads to decreased postoperative morbidity, early convalescence, and decreased postoperative analgesia requirements when compared with conventional laparoscopic approaches.

SILS acronyms

SILS has been described in the literature using many acronyms such as SPA (single port access surgery), LESS (laparoendoscopic single-site surgery), E-NOTES (embryonic natural orifice transumbilical endoscopic surgery), SLIT (single laparoscopic incision

* Corresponding author. KK Women's and Children's Hospital, 100 Bukit Timah Road, Singapore 229899.

E-mail addresses: bernard.chern.sm@kkh.com.sg, liam.toh.gn@kkh.com.sg (B.S.M. Chern).

transabdominal surgery), and SPL (single-port laparoscopy). Recently, an international consortium in Cleveland made a consensus to use the term laparoendoscopic single site surgery (LESS) to include all procedures performed in a minimally invasive manner through a single incision.¹³ The consortium also suggested that the term umbilical laparoendoscopic single-site surgery (U-LESS) be used to describe single-site surgery performed through the umbilicus.

History

The concept of SILS in gynecology dates back to 1969, when Wheelless¹⁴ reported single incision laparoscopy for tubal sterilization. In the 1970s, laparoscopic tubal ligations were performed with Yoon's ring through a single umbilical incision with an offset eyepiece.¹⁵ Pelosi and Pelosi¹⁶ performed total hysterectomy with bilateral salpingo-oophorectomy using the single puncture technique in 1991. However, these procedures did not gain popularity then because of technical challenges. The possibility and ability to perform complex procedures through single-port access has been recently recognized because of remarkable technologic innovations and advancements in the field of laparoscopy. Past limitations included limited instrumentation, lighting, and access ports. In recent years, refinement in conventional laparoscopic techniques and availability of more advanced and sophisticated instruments have made SILS more feasible and safer for patients.

Advantages of SILS

The putative benefits of SILS over conventional laparoscopy include better cosmesis due to relatively hidden umbilical scar, less postoperative pain, rapid convalescence, decreased morbidity related to visceral and vascular injury during trocar placement, risk reduction of postoperative wound infection and hernia formation, and elimination of multiple trocar site closures. Studies have also suggested that women who undergo SILS reported improved postoperative pain profiles when compared with those receiving conventional laparoscopic surgery.^{17,18} This may be due to the utilization of the umbilicus, which is one of the thinnest regions on the abdominal wall containing few blood vessels, muscle, or nerves, as the single site of the incision.

Instruments and technology

Specialized equipments for single-port surgery falls into three broad categories: access ports, scope, and hand instruments.

SILS procedures can be performed via one of two approaches. The first is single-site surgery; more than one conventional port is placed through multiple fascial incisions in a single skin incision. The second approach uses a single, multichannel device, through which multiple instruments and optics can be introduced. The access point for these surgeries is usually the umbilicus, although less cosmetic extraumbilical incisions may occasionally be necessary to complete the surgery. The surge in advancements in access devices, optics, and instrumentation has led to the widespread acceptance of this novel form of laparoscopic surgery.

Single-port devices

SILS can be performed through a variety of access devices. Conventional ports of different lengths can help to minimize limitation of movement by the surgeon due to the extracorporeal crowding and clashing of the instruments and camera (known as sword fighting). Because of technologic developments many multichannel single-port devices have been produced, which are

continuously undergoing modification to meet the ergonomic challenges of SILS.^{19–22}

Multiple standard trocars

Two or three standard 5-mm laparoscopic trocars may be inserted via adjacent fascial incisions through a single umbilical skin incision, providing an alternative means of single-port surgery. This has a cost advantage over the multichannel access ports available, but due to the bulk of the trocars mobility can be limited by clashing ports. In addition, there are multiple fascial incisions to close at completion of surgery, thus potentially causing increased risk of port-site hernia.

TriPort and QuadPort

The TriPort (Advanced Surgical Concepts, Wicklow, Ireland) (Fig. 1) is a multi-instrument access port for laparoscopic surgery. It has two components: a retracting component, which consists of an inner and outer ring with a double-barreled plastic sleeve; and a multichannel valve, which has three valves made of a unique elastomeric material. These valves each accommodate one 12-mm and two 5-mm instruments within the same working space. The port comes in various sizes, ranging from 10 mm to 30 mm, and can be selected according to the size of the fascial incision.

The QuadPort (Advanced Surgical Concepts) (Fig. 2) is another access device that accommodates procedures that require an incision of between 25 mm and 60 mm. The QuadPort sleeve accommodates abdominal wall thicknesses of up to 10 cm. There are four gel valves: one 5 mm (for instruments up to 5 mm in diameter), two 10 mm (accommodates all instruments up to 10 mm), and one 15 mm (accommodates all instruments up to 15 mm). All gel valves are capable of maintaining pneumoperitoneum during instrument exchanges.

TriPort+ is a four-port single-site access device that offers the surgeon a crucial fourth port for retraction in certain procedures. It has three 5-mm valves and one 10-mm valve that is reducible to a 5-mm valve. All valves allow for the use of curved or straight and articulating instruments.

QuadPort+ is a five-port system and offers the surgeon the ability to use a wide range of different diameter instruments. It has two 5-mm valves, one 15-mm valve reducible to a 5 mm valve/one 10-mm valve reducible to a 5-mm valve/one 12-mm valve reducible



Fig. 1. TriPort (Advanced Surgical Concepts, Wicklow, Ireland).

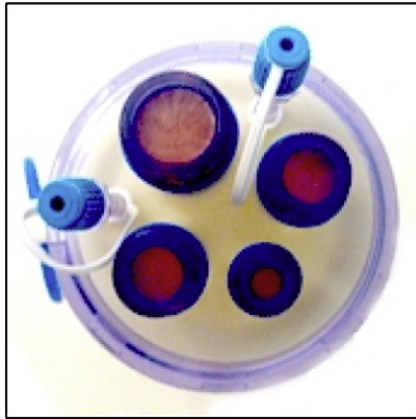


Fig. 2. QuadPort (Advanced Surgical Concepts, Wicklow, Ireland).

to 5 mm valve and can accommodate up to four instruments simultaneously.

TriPort 15 (Fig. 3) is a three-port system that has been designed to facilitate three 5-mm instruments or two 5-mm instruments and a 15-mm instrument, as this device has two 5-mm valves and one 15-mm valve reducible to a 5-mm valve. All valves allow use of curved or straight and articulating instruments. The 15-mm valve accommodates morcellators and staplers.

GelPOINT access system

The GelPort or newer generation GelPOINT (Applied Medical Resources Corp., Rancho Santa Margarita, CA, USA) (Fig. 4) devices consist of a combination of the rigid ring of the Alexis wound retractor with a GelSeal cap that maintains pneumoperitoneum during multiple instrument exchanges. Unlike the aforementioned ports, this system allows for the introduction of ports or instruments of varying shapes and sizes directly through the gel. The advantages of the GelPort system for SILS include the versatility of the GelSeal cap, which enables placement of instruments of different shapes and sizes, and the 10-cm diameter of the outer ring, which reduces instrument crowding. The sealing capacity of the device optimizes instrument exchange via circumferential retraction, facilitating extracorporeal resection and tissue extraction.^{23,24} Escobar et al.²⁵ used the GelPort system for robotic assisted SILS in gynecology, and reported that the larger outside dimension of the GelSeal cap reduces crowding of the robotic arms.



Fig. 3. TriPort 15 (Advanced Surgical Concepts, Wicklow, Ireland).

The GelPOINT access platform is a modification of the GelPort system available for single-port laparoscopy in which, along with the GelSeal cap, four small cannulas are provided by the manufacturer for easier insertion of laparoscopic instruments through the gel interface.

SILS port

The SILS port (Covidien, Mansfield, MA, USA) is another multi-channel access port that allows up to three laparoscopic instruments (three 5-mm cannulas or two 5-mm and one 12-mm cannula) to be used simultaneously through separate flexible channels. The SILS kit (Fig. 5) include the SILS port (Fig. 6) and roticulator instruments. The advantages of the SILS port are that individual ports have conventional laparoscopic seal to minimize the gas leak, open access to the peritoneal cavity is allowed, and there is a dedicated SILS kit with numerous compatible instruments.

Single-site laparoscopy access system

The single-site laparoscopy access system (Ethicon Endosurgery, Cincinnati, OH, USA) (Fig. 7) is another new single-port access system introduced to the market in 2010. This is an abdominal access system composed of a seal cap with accessories (retractor insertion tool and reducer cap), and a fixed-length retractor. The assembled device maintains pneumoperitoneum while allowing for insertion of multiple surgical instruments through a single incision into the abdominal cavity. Features of this seal cap assembly include two 5-mm seals and larger 15-mm seal within an inner seal housing. This exclusive, integrated low-profile device obviates the need for trocars and allows 360° rotation of the seal cap, which reduces the need for instrument changes, allows quick reorientation of instruments during surgery, and also facilitates specimen retrieval.

Operating instruments

The cornerstones of conventional laparoscopic surgery are triangulation and retraction, which are achieved by ports placed far apart. Two of the biggest factors that limit the use of the SILS technique are instrument crowding and lack of triangulation. Standard hand instruments for use in conventional laparoscopy are rigid in design and allow only four degrees of freedom, thus



Fig. 4. GelPOINT (Applied Medical Resources Corp., Rancho Santa Margarita, CA, USA).

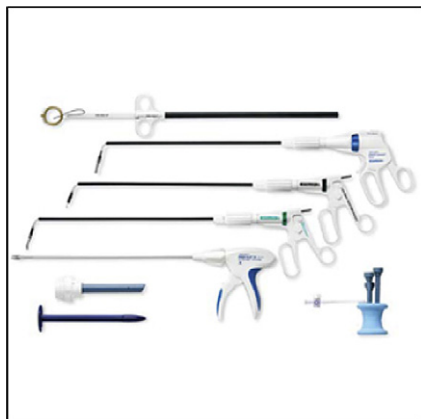

Fig. 5. SILS Kit (Covidien, Mansfield, MA, USA).

limiting the surgeon's dexterity. Articulation is designed to overcome one of the challenges inherent in SILS, decreased triangulation of the instrument.

The Real Hand Instruments (Novare Surgical Systems, Inc., Cupertino, CA, USA) (Fig. 10) are full range of motion, handheld laparoscopic instruments that include ThermoSeal, needle holder, graspers, and dissectors. These multifunctional instruments reduce instrument exchange, allow seven degrees of freedom of movement, and mirror the surgeon's hand movement. These instruments help to overcome the limited triangulation.

Similarly, there are Autonomy Laparo-Angle Instruments (Cambridge Endoscopic Devices, Inc., Framingham, MA, USA) (Fig. 8) that provide seven degrees of freedom, allowing exceptional access to the most difficult-to-reach areas. These instruments also permit full articulation that maps the surgeon's hand motions. These instruments have a tip that can rotate 360° around its axis for precise positioning. With the capability to perform simultaneous actions such as articulating downward while rotating, these are the only currently available instruments with handle that locks at any angle and rotates.

In addition, the SILS Hand Instruments (Covidien) (Fig. 9) enhance the surgeon's flexibility and visualization during complex laparoscopic procedures, including SILS procedures. These instruments offer infinite positions of dynamic articulation within a semihemispherical space and can lock the instrument shaft and angle through an articulation lock lever.

However, a number of factors influence a surgeon's decision to use standard or articulating hand instruments, including which access port they use, individual surgical skills, and cost (articulating



Fig. 6. SILSport (Covidien, Mansfield, MA, USA).



Fig. 7. Single-site laparoscopy access system (Ethicon Endosurgery, Cincinnati, OH, USA).

instruments are significantly more expensive than standard instruments).

Optics

When instruments are passed through a multichannel single port they are more likely to clash with the laparoscope or other instruments because of crowding. Conventional laparoscopes have a large extracorporeal profile with a light cable perpendicular to the telescope and thus, if used for SILS, instrument clashing may be exacerbated.

This can be minimized by either using bariatric-length, rigid, 5-mm telescopes or by using 30-degree scopes, thus widening the field of vision. The crowding can also be offset by using a low-profile camera-scope combination with a coaxial light cord. The latest innovation in this field is EndoEYE (Olympus America Inc., Center Valley, PA, USA), (Fig. 11) which is a specialized laparoscopic camera for SILS with a deflectable tip (Fig. 12). EndoEYE offers a revolutionary, new digital imaging technology that places a miniature CCD chip at the distal tip, making fragile rod lenses a thing of the past. It is available in 5-mm size in 0-degree and 30-degree configurations.

Another special endoscope that may assist in SILS is Stryker's (Kalamazoo, MI, USA) video endoscope system, the IDEAL EYES HD 5-mm articulating laparoscope. Designed for utility and comfort, this laparoscope features an angled handle and friction-assist control levers that help place and fix the articulating tip with great precision—helping to control image selection and improve horizon maintenance. The combined light source/video cable minimizes cable clutter and instrument clashing.

Review of published reports of SILS in benign gynecology

Although SILS is a relatively new field, there has been an increase in the number and variety of SILS surgeries reported in gynecology.

Wheless¹⁴ reported the first single-incision laparoscopic tubal sterilization in 1969 and later Wheless and Thompson²⁶ reported a series of 3600 women undergoing single-port laparoscopic sterilization.

Traditionally, laparoscopic salpingectomy for treatment of tubal ectopic pregnancy was performed using two ancillary trocars. In 2005, Ghezzi et al²⁷ reported a novel single-port technique using only an umbilical surgical laparoscope and a percutaneous midline suture, inserted with a straight needle, to retract the affected fallopian tube. They successfully treated 10 ectopic pregnancies with this technique. Further refinements in this treatment modality for

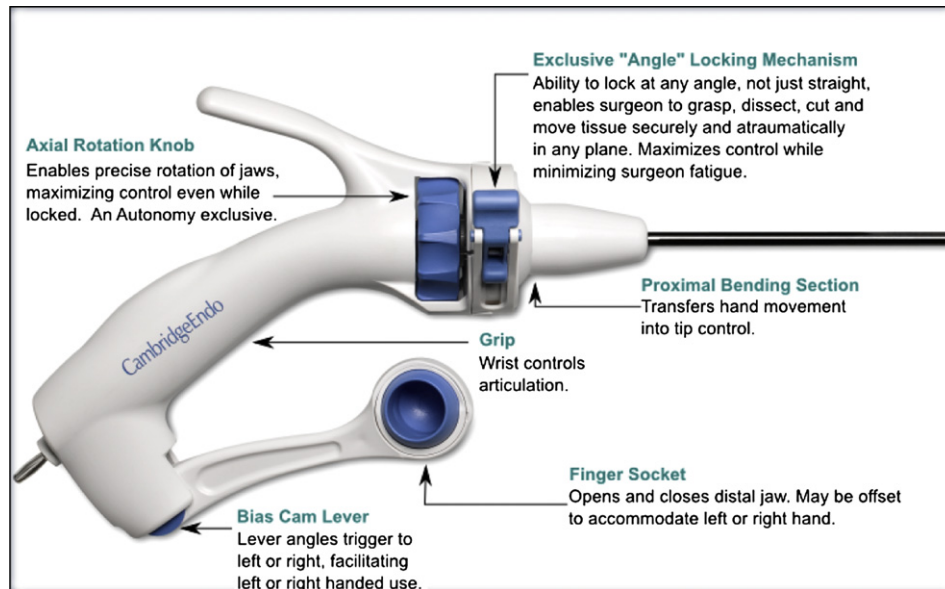


Fig. 8. Autonomy Laparo-Angle Instruments (Cambridge Endoscopic Devices, Inc., Framingham, MA, USA).

ectopic pregnancy have been cited in various case studies and cohorts either using single-site access with multiple fascial punctures or single-port techniques, proving that laparoscopic salpingectomy can be safely and easily accomplished using SILS.^{28,29} They found that the only limitation to the feasibility of this procedure could be the presence of dense pelvic adhesions obscuring the ectopic gestation and thus requiring an additional port for adhesiolysis.

Yoon et al²⁹ reported a series of 20 women with tubal pregnancy who were treated with single-port laparoscopic salpingectomy. They operated through a single port composed of an Alexis wound retractor and surgical glove. In their single-port procedure, instrument access was achieved with two channels, simulating conventional laparoscopy and thus was feasible despite of pelvic adhesions. The use of the wound retractor and glove assembly obviated the need for expensive multichannel single-port systems as well as helped overcome the parallel placement of surgical instruments. The first case of single-incision laparoscopic excision of cornual ectopic pregnancy was reported by Chern et al.³⁰

In 2001, Kosumi et al³¹ reported ovarian cystectomy through a single incision using a surgical laparoscope. Since then various case reports and studies have described SILS in adnexal surgery for benign pathologies, including unilateral or bilateral salpingo-

oophorectomy, adhesiolysis, excision of endometriosis, and ovarian cystectomy.^{32–35} Fagotti et al³² reported that laparoendoscopic single-site enucleation of large ovarian cysts with ovary sparing is feasible with standard laparoscopic instruments. It is safe and effective, with good results in terms of cosmesis and postoperative pain. Escobar et al,³³ in their retrospective study of SILS in benign adnexal disease, concluded that SILS is feasible in select patient with endometriosis or benign adnexal disease. Eight of nine cases were completed successfully, without conversion to a standard laparoscopic approach or to laparotomy. An additional 3-mm extraumbilical port was required in one patient with Stage 4 endometriosis. Seven of nine patients had previous abdominal surgery. The surgical blood loss ranged from minimal to 75 mL. Duration of hospital stay was <24 hours in all cases. Minimal use of postoperative narcotics was required, and no intraoperative complications occurred. Their findings of excellent cosmesis, less postoperative pain, minimal use of narcotics, shorter hospital stay, and fewer complications were consistent with Fagotti et al.³²

Mereu et al³⁵ described the use of reusable S-Portal X-cone (Karl Storz, Tuttlingen, Germany) and curved instruments for their study of 16 patients with adnexal pathologies. Port placement was successful in all patients and the mean time for introduction of the trocar was 3.2 minutes (range, 2–9 minutes). Mean surgical time from incision to closure was 42 minutes (range, 20–72 minutes) and estimated blood loss was less than 10 mL per patient. Port placement time and overall surgical time decreased over the study period. The median satisfaction values reported by the patients at discharge for cosmetic appearance and postoperative pain were 9 (range, 5–10) and 7 (range, 2–10), respectively. They concluded that SILS provide an opportunity to further enhance the cosmetic benefits of minimally invasive surgery while minimizing the potential morbidity associated with multiple incisions. Compared with studies by Fagotti et al³² and Fader et al,³⁶ they achieved a shorter surgical time with a quick learning curve, which they attributed to the use of specialized instruments and techniques to increase the correct surgical ergonomics, such as the surgeon's position and standardization of instrument placement in the port accesses.

Kim et al³⁴ used a specially designed single-port platform, which consists of a wound retractor and a surgical glove for their study of 24 well-selected patients with adnexal masses and found

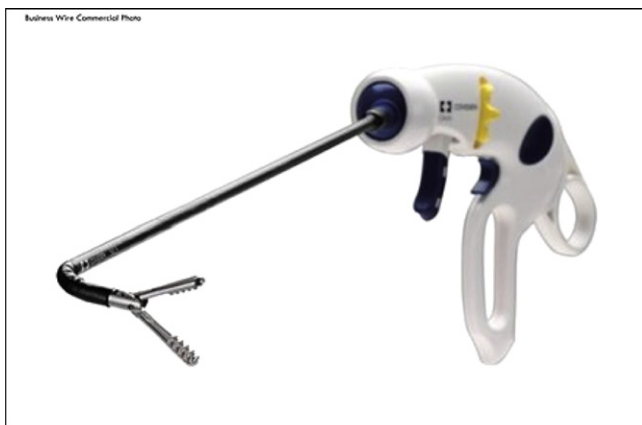

Fig. 9. SILS Hand Instruments (Covidien, Mansfield, MA, USA).




Fig. 10. The Real Hand Instruments (Novare Surgical Systems, Inc., Cupertino, CA, USA).

that SILS laparoscopic surgery was safe and feasible and provided almost no visual scar. The median tumor size was 5 cm (range 3–12 cm), the median surgical time was 70 minutes (range 40–128 minutes), and the estimated blood loss was minimal (range 10–100 mL). The postoperative course was uneventful in all patients. The median postoperative hospital stay was 1 day (range 1–3 days). No postoperative complications were observed at follow-up. There were two failed cases; one required an additional port for adhesiolysis and the other a staging laparotomy because of the finding of a borderline ovarian malignancy on frozen section pathologic study.

Limitations to these reports include small number of cases and their retrospective design, thus being susceptible to biases inherent to such studies. Although results are quite promising in terms of safety, cosmesis, and postoperative pain, some studies suggest technical challenges in cystectomy owing to suboptimal traction-countertraction required for cyst enucleation.

Pelosi and Pelosi¹⁶ reported first single-port supracervical hysterectomy in four patients in 1991. Application of SILS for hysterectomy has been reported for both total laparoscopic hysterectomy (TLH) and laparoscopic-assisted vaginal hysterectomy (LAVH) through various case reports and case series.^{18,37–45}

Kim et al³⁷ recently published a comparative study of LESS versus conventional laparoscopy in cases of LAVH. The mean (standard deviation) visual analog scale–based pain scores at 24 and 36 hours after surgery were lower in the LESS group. Other intraoperative and perioperative outcomes were similar in the two groups. Yim et al¹⁸ also published a study comparing surgical outcomes and postoperative pain between transumbilical single-port access total laparoscopic hysterectomy (SPA-TLH) and conventional four-port TLH. The SPA-TLH group had less intraoperative blood loss, shorter hospital stay, and earlier diet intake compared with the conventional TLH group. There was no difference in perioperative complications. Immediate postoperative pain score was lower in the SPA-TLH group. Postoperative pain after 6 and 24 hours was lower in SPA-TLH with marginal statistical significance.

Song et al³⁸ reported their technique of single-port laparoscopic assisted vaginal hysterectomy in women with a large uterus weighing more than 500 g. Thirteen of the 15 patients enrolled successfully underwent the single-port procedure; two patients required additional ports. The median (range) surgical time was 125 (80–236) minutes, uterine weight was 690 (503–1260) g, and estimated blood loss was 500 (150–1000) mL. No perioperative




Fig. 11. EndoEYE (Olympus America Inc., Center Valley, PA, USA) with coaxial light cable.




Fig. 12. Deflectable-tip EndoEYE.

complications were reported. Yoon et al.³⁹ evaluated the feasibility, safety, and surgical outcome of management of myomas and adenomyosis using single-port access subtotal hysterectomy with transcervical morcellation using a wound retractor and a surgical glove. Their study concluded that single-port access subtotal hysterectomy is as safe and effective as conventional LAVH and results in almost no visible scar. Lee et al.⁴⁰ have described single-port access LAVH using a wound retractor and glove in 24 patients and concluded that it was safe and effective, and the procedure could be learned over a short period of time.

Langebrekke⁴¹ reported TLH through single-port access without vaginal surgery in which the vaginal cuff was closed using bidirectional self-retaining sutures. The technique of TLH is possible with single-port access; however, most surgeons find the suture technique difficult through a single port. Compared with traditional sutures, the benefits of the bidirectional self-retaining sutures with tissue retainers (barbs) include speed and economy of suture placement. There is no need for suture knotting, and by not using multiple suture loops, the tension can be more uniformly distributed along the length of the vaginal cuff. They found that surgical time in first-described single-access hysterectomy with laparoscopic closure of cuff was 60 minutes, which was approximately 15 minutes longer than expected using the multiport technique.

Kim et al.^{46,47} first reported single-port laparoscopic myomectomy using conventional rigid straight laparoscopic instruments and a new single-port transumbilical morcellation system. In their study of 15 patients, all procedures were performed by a single surgeon. The current study demonstrated that single-port laparoscopic myomectomy is a safe and effective alternative to conventional laparoscopic myomectomy in a selected group of patients with myomas of maximum diameter of 9.6 cm. A single-port system created with a wound retractor and a surgical glove made transumbilical myoma morcellation and extraction possible. They found that it was not necessary to perform culdotomy for extraction through the vagina. The wound retractor widens the umbilical incision, which enables simultaneous transit of several laparoscopic instruments including a conventional electromechanical morcellator that can be as large as 15 mm into a small umbilical incision. The study established that although conventional laparoscopic myomectomy has proved advantageous over abdominal myomectomy in terms of less morbidity, less postoperative pain, and shorter hospital stay in selected group of patients, however, in single-port laparoscopic myomectomy, it could be more difficult to handle instruments for cleavage of large myomas, surgical time might be longer, and bleeding could be increased compared with multiport laparoscopic myomectomy. They also concluded that more often single-port laparoscopic myomectomy is performed, the more feasible it shall become.

The difficulty with laparoscopic myomectomy is the requirement for significant intracorporeal suturing for uterine closure. The single-incision technique adds an extra dimension of difficulty to this step.⁴⁸ The myometrium can be closed with barbed suture which has been shown to be feasible and faster for myomectomies.⁴⁹ The use of bidirectional barbed suture is safe for uterine closure and facilitates closure by preventing backsliding of the suture and eliminating the need for knot tying.⁵⁰

Review of published reports of SILS in gynecologic oncology

Fader and Escobar³⁶ presented the first series of LESS for various gynecologic cancers or precancerous conditions, through both laparoscopic and robotic-assisted approaches. Thirteen patients underwent single-port surgery, nine performed laparoscopically and four with robotic assistance. Procedures included endometrial cancer staging ($n = 1$), ovarian cancer staging ($n = 1$),

retroperitoneal pelvic lymph node dissection ($n = 1$), risk-reducing extrafascial hysterectomy/bilateral salpingo-oophorectomy (BSO, $n = 2$) and BSO alone ($n = 5$), and an ovarian cystectomy ($n = 1$) and BSO ($n = 2$) for complex adnexal masses. Median patient age and body mass index (BMI) were 47 years and 28, respectively. Median operating time was 65 minutes. All procedures were successfully performed via a single incision and no postoperative complications occurred. Most patients required no narcotics postoperatively.

Recently, Escobar et al.⁵¹ reported more complicated gynecologic procedures such as pelvic and para-aortic lymphadenectomy using SILS technique. Twenty-one patients with apparent early-stage gynecologic malignancies who required pelvic and/or para-aortic lymph node sampling or lymphadenectomy, underwent single-port surgery/staging during the study period. In their preliminary report, Escobar et al. concluded that the technique was feasible and no morbidity was noted. These procedures produced comparable nodal counts to open or conventional laparoscopic surgery. One limitation of LESS for nodal dissection was that visceral and truncal adiposity limited the access to the left para-aortic nodal region, and therefore, this procedure may be difficult to perform in morbidly obese woman using single-port techniques. However, further studies are needed to better define the ideal gynecologic oncology procedures for single-site surgery and to assess the relative benefits of this new technique compared with more conventional minimally invasive approaches.

Finally, there are also reports of single-access surgery performed with the da Vinci surgical system robotic platform. Escobar et al.²⁵ first reported a robotic SILS gynecologic procedure using the da Vinci S robot (Intuitive Surgical Inc., Sunnyvale, CA, USA) and Gel-Seal cap. They performed TLH with BSO. They found that the adaptability of the current da Vinci system, and colpotomy for extraction of specimen for LESS, makes robotic-assisted single-port surgery feasible. The studies from Escobar et al.³⁶ and Stein et al.²⁰ concluded that GelPort provided the best access platform for robotic docking and triangulation of robotic ports.

Technical challenges and strategies

Despite the refinements and advancements in techniques and instrumentation, single-port surgery still poses technical challenges to the surgeon. The following are the most commonly confronted technical difficulties in single-port surgery.

1. The major hurdle in this new surgical technique is the sacrifice in terms of surgeon's comfort and ergonomics. Crowding and clashing of instruments at single incision leaves less room for movement and maneuverability. There are a few ways to overcome instrument crowding. A long bariatric-length scope or instruments can be used to prevent clashing of instruments and telescope. The GelPOINT access device with larger outer cap can be used, which increases the distance between instruments. In addition, with the new SSL Access system from Ethicon (Cincinnati, OH, USA), the need for trocars is obviated. Its outer sealcap can be rotated by 360 degrees, thus eliminating the need for changing instruments, and can be quickly rotated to reorient the instruments. This clashing of instruments can also be avoided by using streamlined low-profile telescope with coaxial light cable as in the Olympus EndoEYE.
2. Lack of triangulation is inherent to single-port surgery. Even with current advancements in various access ports, deflecting tip streamlined cameras, and articulating instruments, adequate triangulation still cannot be achieved. However, with the development of proximally deviating curved coaxial instruments with double bending, it is anticipated that this hurdle will be overcome to a large extent. The first generation

of curved instruments included the X-cone (Fig. 13) access port and S-portal curved instruments (Karl Storz).

3. Similarly, the surgeon's right hand will control the left-sided instruments on the screen and the left hand will control the right-sided instruments on screen.⁵² The use of such crossover instruments requires longer surgery times and is quite challenging ergonomically.

These technical difficulties do make SILS a more demanding procedure than a conventional laparoscopy and thus requires an ongoing surge of strategies for enhancement of techniques and instruments to overcome these challenges.

Patient selection criteria for SILS

Initial reports in gynecology have gone to prove that obesity, previous abdominal surgeries, and a diagnosis of early-stage malignancy does not necessarily preclude the use of SILS.^{18,25,42} Escobar et al.³⁶ found no difference in outcomes between groups for BMI, comorbidities, or previous surgeries. However, patients with high BMI represent a very challenging group of patients for SILS. Patients with BMI less than 26–28 kg/m² are the ideal candidates for this approach.⁵³ Patients with higher BMI have a higher risk of having thick abdominal wall or a large amount of intraperitoneal fat, thus making access and exposure difficult, respectively.

Patients with previous laparotomy present another challenging group because of their increased likelihood of having intraperitoneal adhesions. Thus, women with previous two or more laparotomies, high BMI, and who do not possess a native umbilicus or have advanced stage of malignancy may not be suitable candidates for single-port surgery.

The learning curve

SILS is an emerging technique posing new challenges to laparoscopy and introduces new skills that surgeons must acquire. The learning needs for single-incision skill acquisition are unknown and no current guidelines exist for training or its safe adoption.⁵⁴ Given the high level of technical skills and training required for SILS, the learning curve may be long and difficult.



Fig. 13. X-Cone access port and S-portal curved instruments (Karl Storz, Tuttlingen, Germany), the first generation of curved coaxial instruments with proximal bending.

Fader and Escobar,⁴² in their study of 74 cases, described a learning curve analysis of cancer staging procedures and non-staging procedures. The surgical times for single-port insertion and LESS TLH/BSO decreased significantly across all quartiles, although the most dramatic reductions in times were observed between the first 10 cases and next 10 cases. There was a strong linear correlation between surgical time and number of cases performed for both staging and nonstaging procedures. Based on Pearson correlation coefficient analysis, it appears that decrease in surgical times appeared to stabilize after 20 cases. These preliminary results suggest a similar learning curve for conventional laparoscopy and LESS procedures to that of Hasson trocar placement.

Another study from Santos et al.⁵⁵ demonstrated that standard laparoscopic technique had a shorter learning curve compared with SILS. SIL-specific simulator training is better than conventional laparoscopic surgery training alone to improve SILS performance.

Hence, it is crucial that surgeons attempting this new surgical technique should be at least highly dexterous in conventional laparoscopy. Furthermore, it is also recommended to have practice sessions and hands-on courses in a dry laboratory setting. In addition, working with or assisting or observing more experienced surgeons in SILS on several cases may help in learning the technical challenges and the ways to overcome them. To start with simple cases in suitable patients may make learning these ergonomically challenging techniques probably less technically demanding.

Future trends

Tremendous technologic advancements have led to widespread acceptance of SILS in various fields.

Specialized multichannel access ports (Fig. 14) and reticulating instruments (Fig. 15) have helped overcome the various ergonomic challenges of single-incision laparoscopic surgery. Robotic-assisted SILS is a new venture to further overcome the limitations of single-incision surgery with the aid of improved dexterity and ergonomics of robotic surgery. The newer-generation da Vinci robot may have single-port adaptation that will allow for more feasibility with SILS and may ease some of the challenging ergonomic issues associated with conventional SILS.

SurgiQuest, Inc. is building a custom laparoscopic port for Intuitive Surgical's da Vinci robotic system. Based on SurgiQuest's (Milford, CT, USA) AirSeal, the goal of the new product is to provide single port access with a clearer camera view and a greater range of motion. The AirSeal recirculates and filters peritoneal gas providing for improved visibility, keeps the scope free from obstructions, monitors abdominal pressure in real time, which allows the insufflator to adjust as needed to ensure a stable pneumoperitoneum. Its invisible barrier allows hassle-free insertion of gauze, mesh or drains — even multiple instruments — without friction and interference and with greater freedom of movement. Ongoing research on flexible robotic systems and miniature deployable robots shall make SILS more feasible in gynecology.

With ongoing efforts to decrease the size and number of incisions, improve patient outcome, and increase patient satisfaction, SILS represents the next leap in laparoscopic surgery. Various studies available to date have proven the safety, feasibility, and improved postoperative outcomes when offered for a variety of gynecologic procedures, including for the treatment of select malignancies. The goal of SILS is to improve patient outcome by decreasing postoperative pain, analgesia requirements, rapid convalescence, and superior cosmesis through a hidden tiny scar in the umbilicus. Although SILS provides improved cosmesis and decreased morbidity as compared with conventional laparoscopy, larger randomized controlled trials and prospective studies are needed to assess the safety, feasibility and cost-effectiveness of this




Fig. 14. Future single port.

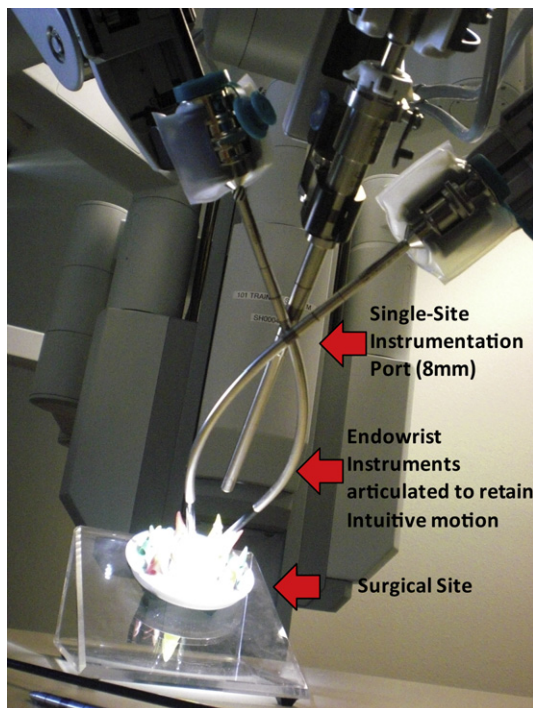


Fig. 15. Single-site instrumentation recently released.

newfound revolutionary technique. Although SILS may offer a subjective cosmetic benefit, validated patient-outcome questionnaires are necessary to more objectively address this point. The routine application of SILS in various gynecologic procedures requires further research to determine its clinical and economic effect. A greater learning curve, additional experience and continued investigation are warranted.

SILS has made its initial incursion into laparoscopic surgery. We should remain enthusiastic about the potential benefits and possibilities of SILS and anticipate that ongoing developments in laparoscopic techniques and instrumentation is likely to expand its role in future in various gynecologic conditions.

References

1. Cho YH, Kim DY, Kim JH, Kim YM, Kim YT, Nam JH. Laparoscopic management of early uterine cancer: 10-year experience in Asan Medical Center. *Gynecol Oncol*. 2007;106:585–590.
2. Kalogiannidis I, Lambrechts S, Amant F, Neven P, Van Gorp T, Vergote I. Laparoscopy-assisted vaginal hysterectomy compared with abdominal hysterectomy in clinical stage I endometrial cancer: safety, recurrence, and long-term outcome. *Am J Obstet Gynecol*. 2007;196:248.

3. Walker JL, Piedmonte MR, Spirtos NM, et al. Laparoscopy compared with laparotomy for comprehensive surgical staging of uterine cancer: gynecologic oncology group study LAP2. *J Clin Oncol*. 2009;27:5331–5336.
4. Bessler M, Stevens PD, Milone L, Parikh M, Fowler D. Transvaginal laparoscopically assisted endoscopic cholecystectomy: a hybrid approach to natural orifice surgery. *Gastrointest Endosc*. 2007;66:1243–1245.
5. Inoue H, Takeshita K, Endo M. Single-port laparoscopy assisted appendectomy under local pneumoperitoneum condition. *Surg Endosc*. 1994;8:714–716.
6. Rao MM, Rao RK. Two-port and single port laparoscopic appendectomy. *J Indian Med Assoc*. 2004;102:360, 362, 364.
7. Podolsky ER, Rottman SJ, Poblete H, King SA, Curcillo PG. Single Port Access (SPA) cholecystectomy: a completely transumbilical approach. *J Laparoendosc Adv Surg Tech*. 2009;19:219–222.
8. Canes D, Desai MM, Aron M, et al. Transumbilical single-port surgery: evolution and current status. *Eur Urol*. 2008;54:1020–1029.
9. Kommu SS, Kaouk JH, Rané A. Laparo-endoscopic single-site surgery: preliminary advances in renal surgery. *BJU Int*. 2009;103:1034–1037.
10. Romanelli JR, Roshek TB 3rd, Lynn DC, Earle DB. Single-port laparoscopic cholecystectomy: initial experience. *Surg Endosc*. 2010;24:1374–1379.
11. Canes D, Berger A, Aron M, et al. Laparo-endoscopic single site (LESS) versus standard laparoscopic left donor nephrectomy: matched-pair comparison. *Eur Urol*. 2010;57:95–101.
12. Teixeira J, McGill K, Binenbaum S, Forrester G. Laparoscopic single-site surgery for placement of an adjustable gastric band: initial experience. *Surg Endosc*. 2009;23:1409–1414.
13. Gill IS, Advincula AP, Aron M, et al. Consensus statement of the consortium for laparoendoscopic single-site surgery. *Surg Endosc*. 2010;24:762–822.
14. Wheelerless C. A rapid, inexpensive, and effective method of surgical sterilization by laparoscopy. *J Reprod Med*. 1969;5:255.
15. Quinones GR, Alvarado DA, Ley Ch E. Tubal ligation using Yoon's ring. *Ginecol Obstet Mex*. 1976;40:127–136.
16. Pelosi MA, Pelosi MA 3rd. Laparoscopic hysterectomy with bilateral salpingo-oophorectomy using a single umbilical puncture. *N J Med*. 1991;88:721–726.
17. Kim YW, Park BJ, Ro DY, Kim TE. Comparison of single-port transumbilical laparoscopically assisted vaginal hysterectomy (SPLAVH) and laparoscopically assisted vaginal hysterectomy (LAVH). *J Minim Invasive Gynecol*. 2009;16: S103–S157.
18. YIM GW, Jung YW, Paek J, et al. Transumbilical single-port access versus conventional total laparoscopic hysterectomy: surgical outcomes. *Am J Obstet Gynecol*. 2010;203:e1–e6.
19. Dutta S. Early experience with single-incision laparoscopic surgery: eliminating the scar from abdominal operations. *J Ped Surg*. 2009;44:1741–1745.
20. Stein RJ. Robotic laparoendoscopic single-site surgery using gelport as the access platform. *Eur Urol*. 2010;57:132–137.
21. Merchant AM. Transumbilical gelport access technique for performing single-incision laparoscopic surgery (SILS). *J Gastrointest Surg*. 2009;13:159–162.
22. Rettenmaier MA. A Retrospective review of the Gelport system in single-port access pelvic surgery. *J Minim Invasive Gynecol*. 2009;16:743–747.
23. Nakajima K, Lee SW, Cocilovo C, et al. Hand-assisted laparoscopic colorectal surgery using GelPort. *Surg Endosc*. 2004;18:102–105.
24. Pelosi MA, Pelosi MA. Hand assisted laparoscopy for complex hysterectomy. *J Am Assoc Gynecol Laparosc*. 1999;6:183–188.
25. Escobar PF, Fader AN, Paraiso MF, Kaouk JH, Falcone T. Robotic assisted laparoendoscopic single-site surgery in gynecology: initial report and technique. *J Minim Invasive Gynecol*. 2009;16:589–591.
26. Wheelerless CR Jr, Thompson BH. Laparoscopic sterilization. Review of 3600 cases. *Obstet Gynecol*. 1973;42:751–758.
27. Ghezzi F, Cromi A, Fasola M, Bolis P. One-trocar salpingectomy for the treatment of tubal pregnancy: a "marionette-like" technique. *BJOG*. 2005;112:1417–1419.
28. Savaris RF, Cavazzola LT. Ectopic pregnancy: laparoendoscopic single-site surgery-laparoscopic surgery through a single cutaneous incision. *Fertil Steril*. 2009;92:1170–e5–e7.
29. Yoon BS, Park H, Seong S. Single-port laparoscopic salpingectomy for the surgical treatment of ectopic pregnancy. *J Minim Invasive Gynecol*. 2010;17: 26–29.
30. Chern SBM, Teo S, Tan KH. Single-port laparoscopic excision of cornual pregnancy: a case report. *SJOG*; 2009.
31. Kosumi T, Kubota A, Usui N, Yamauchi K, Yamasaki M, Oyanagi H. Laparoscopic ovarian cystectomy using a single umbilical puncture method. *Surg Laparosc Endosc Percutan Tech*. 2001;11:63–65.
32. Fagotti A, Fanfani F, Marocco F, Rossitto C, Gallotta V, Scambia G. Laparoendoscopic single-site surgery (LESS) for ovarian cyst enucleation: report of first three cases. *Fertil Steril*. 2009;92:116.
33. Escobar PF, Bedaiwy M, Fader AN, Falcone T. Laparoendoscopic single site (LESS) in patients with benign adnexal disease. *Fert Steril*. 2010;93:2071.
34. Kim TJ, Lee YY, Kim MJ, et al. Single port access laparoscopic adnexal surgery. *J Minim Invasive Gynecol*. 2009;16:612–615.
35. Mereu L, Angioni S, Melis GB, Mencaglia L. Single access laparoscopy for adnexal pathologies using a novel reusable port and curved instruments. *Int J Gynaecol Obstet*. 2010;109:78–80.
36. Fader AN, Escobar PF. Laparoendoscopic single-site surgery (LESS) in gynecologic oncology: technique and initial report. *Gynecol Oncol*. 2009;114:157–161.
37. Kim TJ, Lee YY, Cha HH, et al. Single-port-access laparoscopic assisted vaginal hysterectomy versus conventional laparoscopic assisted vaginal hysterectomy: a comparison of perioperative outcomes. *Surg Endosc*. 2010;24:2248–2252.

38. Song T, Kim TJ, Kim MK, et al. Single port access laparoscopic assisted vaginal hysterectomy for large uterus weighing exceeding 500 grams: technique and initial report. *J Minim Invasive Gynecol.* 2010;17:456–460.
39. Yoon G, Kim TJ, Lee YY, et al. Single-port access subtotal hysterectomy with transcervical morcellation: a pilot study. *J Minim Invasive Gynecol.* 2010;17:78–81.
40. Lee YY, Kim TJ, Kim CJ, et al. Single-port access laparoscopic-assisted vaginal hysterectomy: a novel method with a wound retractor and a glove. *J Minim Invasive Gynecol.* 2009;16:450–453.
41. Langebrekke A, Qvigstad E. Total laparoscopic hysterectomy with single-port access without vaginal surgery. *J Minim Invasive Gynecol.* 2009;16:609–611.
42. Fader AN, Rojas-Espallat L, Ibeanu O, Grumbine F, Escobar PF. Laparoendoscopic single-site surgery (LESS) in gynecology: a multi-institutional evaluation. *Am J Obstet Gynecol.* 2010;203:501.e1–6.
43. Fanfani F, Fagotti A, Scambia G. Laparoendoscopic single-site surgery for total hysterectomy. *Int J Gynecol Obstet.* 2010;109:76–77.
44. Jung YW, Kim YT, Lee DW, et al. The feasibility of scarless single-port transumbilical total laparoscopic hysterectomy: initial clinical experience. *Surg Endosc.* 2010;24:1686–1692.
45. Koyanagi T, Motomura S. Transumbilical single-incision laparoscopic surgery: application to laparoscopically assisted vaginal hysterectomy. *Arch Gynecol Obstet.* 2011;283:305–309.
46. Kim YW. Single port transumbilical myomectomy and ovarian cystectomy. *J Minim Invasive Gynecol.* 2009;16:574.
47. Kim YW, Park BJ, Ro DY, Kim TE. Single-port laparoscopic myomectomy using a new single-port transumbilical morcellation system: initial clinical study. *J Minim Invasive Gynecol.* 2010;17:587–592.
48. Einarsson Ji. Single-incision laparoscopic myomectomy. *J Minim Invasive Gynecol.* 2010;17:371–373.
49. Alessandri F, Remorgida V, Venturini PI, Ferrero S. Unidirectional barbed suture versus continuous suture with intracorporeal knots in laparoscopic myomectomy: a randomized study. *J Minim Invasive Gynecol.* 2010;17:725–729.
50. Greenberg JA, Einarsson JI. The use of bidirectional barbed suture in laparoscopic myomectomy and total laparoscopic hysterectomy. *J Minim Invasive Gynecol.* 2008;15:621–623.
51. Escobar PF, Fader AN, Rojas L. LESS pelvic and para-aortic lymphadenectomy. *Int J Gynecol Oncol.* 2010;20:1268–1273.
52. Chow A, Aziz O, Purkayastha S, Darzi A, Paraskeva P. Single incision laparoscopic surgery for acute appendicitis: feasibility in pediatric patients. *Diagn Ther Endosc.* 2010;2010:294958.
53. Ross SB, Clark CW, Morton CA, Rosemurgy AS. Access for laparoendoscopic single site surgery. *Diagn Ther Endosc.* 2010;2010:943091.
54. Khandelwal S, Wright AS, Figueredo E, Pellegrini CA, Oelschlager BK. Single incision laparoscopy; training, techniques, and safe introduction to clinical practice. *J Laparoendosc Adv Surg Tech A.* 2011;21:687–693.
55. Santos BF, Reif TJ, Soper NJ, Hungness ES. Effect of training and instrument type on performance in single-incision laparoscopy: results of a randomized comparison using a surgical simulator. *Surg Endosc.* 2011;25:3798–3804.