



## Original article

## One-step hysteroscopic myomectomy using Lin dissecting loop and Lin myoma graspers

Bao-Liang Lin<sup>a,\*</sup>, Takayuki Higuchi<sup>a</sup>, Akira Yabuno<sup>a</sup>, Kana Kashinoura<sup>a</sup>, Takeshi Suzuki<sup>a</sup>, Seon-Hye Kim<sup>a</sup>, Sokichi Iwata<sup>a</sup>, Yun Zhao<sup>b</sup>

<sup>a</sup> Department of Obstetrics and Gynecology, Kawasaki Municipal Hospital, Kawasaki, Japan

<sup>b</sup> Department of Obstetrics and Gynecology, Kiang Wu Hospital, Macau, China

## ARTICLE INFO

## Article history:

Received 24 August 2011

Received in revised form

15 May 2012

Accepted 20 May 2012

Available online 1 October 2012

## Keywords:

Hysteroscopic myomectomy

Hysteroscopy

Submucous myoma

## ABSTRACT

**Objective:** To evaluate the efficacy of hysteroscopic myomectomy using the Lin dissecting loop and Lin myoma graspers to remove myoma in a single procedure.

**Materials and Methods:** This was a retrospective study performed in the gynecologic department of a general hospital. A total of 1569 women with submucous myoma or symptomatic intramural myoma underwent one-step resectoscopic myomectomy using Lin dissecting loop and Lin myoma graspers.

**Results:** Of the 1569 patients, pedunculated submucous myoma, sessile submucous myoma, and intramural myoma were diagnosed in 943, 608, and 19 patients, respectively. The patients' median age was 38.6 years (range 19–59 years). The operating time was between 4 minutes and 147 minutes (mean  $30.6 \pm 18.2$  minutes). The specimen weighed from 0.1 g to 380 g (mean  $19.9 \pm 21.4$  g). Two uterine perforations caused by myoma graspers were encountered. No fluid complications were experienced. Almost all of the patients had improvement of symptoms. Long-term follow-up revealed five cases of abdominal total hysterectomy, one case of abdominal myomectomy, 21 cases of re-hysteroscopic operation, 59 cases of normal spontaneous delivery, 36 cases of cesarean section, five cases of ongoing pregnancy, and one case of spontaneous abortion. No case of uterine rupture was encountered. There was one case of placenta accreta that required hysterectomy.

**Conclusion:** Using our technique and instruments, it is possible to remove a myoma in a single procedure safely and effectively. This surgical method can also preserve more endometrium, cause less injury to the muscle layer, and prevent fluid complications.

Copyright © 2012, The Asia-Pacific Association for Gynecologic Endoscopy and Minimally Invasive Therapy. Published by Elsevier Taiwan LLC. All rights reserved.

## Introduction

Submucous myoma, regardless of its size, frequently causes menorrhagia and metrorrhagia, and sometimes results in infertility. To date, hysteroscopic myomectomy has been regarded as the standard procedure to treat these myomas.<sup>1,2</sup> Usually a resectoscope is used to shave the myoma from its most protruded area in the uterine cavity. Hence, the degree of its uterine protrusion determines the feasibility of this procedure. In the case of a broad-based, deeply invaded submucous myoma, also termed a sessile myoma, it is rather difficult to remove the myoma completely in

one hysteroscopic procedure. Two or more steps are usually required. In 2000, we published our technique of one-step hysteroscopic myomectomy<sup>3</sup> which is the same as that used to perform an abdominal or laparoscopic myomectomy. After that, several Lin instruments were designed to facilitate the operation. We present our experience of how to remove a submucous myoma completely in a single procedure using these instruments.

## Materials and methods

From October 2003 to December 2011, 1569 consecutive patients who had been referred to our gynecologic department and satisfied the following surgical indications were enrolled in the study.

Indications for hysteroscopic myomectomy:

1. Uterine size  $\leq 12$  weeks' gestational size; cavity length  $< 12$  cm.

\* Corresponding author. Department of Obstetrics and Gynecology, Kawasaki Municipal Hospital, 12-1, Shinkawadori, Kawasaki-Ku, Kawasaki 210-0013, Japan.

E-mail address: [Lin@beige.ocn.ne.jp](mailto:Lin@beige.ocn.ne.jp) (B.-L. Lin).

2. The largest diameter of the myoma <60 mm (if intrauterine protrusion >50%).
3. The largest diameter of the myoma ≤40 mm in diameter (if intrauterine protrusion ≤50%).
4. Symptomatic intramural myoma ≤30 mm in diameter.
5. Serosa-myoma thickness (SMT) ≥5 mm.
6. No existence of uterine malignancy.

#### Preoperative assessments

##### Office hysteroscopy

A 3.1 mm flexible hysteroscope (Olympus Optical Co., Tokyo, Japan) was used without cervical dilation or anesthesia to confirm the location, size and the number of the myoma. If necessary, a directed biopsy was done to rule out endometrial malignancy. According to our classification, the ratio of intrauterine protrusion of the myoma was estimated (Fig. 1). Pedunculated submucous myoma is defined to the myoma with the ratio of intrauterine protrusion larger than 50%. Sessile submucous myoma is defined to its protrusion ratio smaller or equal to 50%.

##### Ultrasound examinations

Immediately after diagnostic hysteroscopy both abdominal and vaginal ultrasonographies (sonohysterography)<sup>4</sup> were done to evaluate the size of the uterus, the number, location and size of the myoma, and the SMT<sup>5</sup> (Fig. 2).

##### Magnetic resonance imaging (MRI)

MRI, which is now a very popular examination in Japan, was not used as a routine examination. It was done for those patients with multiple myomas or suspicion of other pathologic lesions such as uterine sarcoma. (Fig. 3)

##### Pap smear and endometrial cytologic or pathologic examination

To exclude uterine malignancy, these examinations were done on the patient's first visit if she had not been already received the examinations yet.

##### Preoperative treatment with gonadotropin-releasing hormone analogue

Gonadotropin-releasing hormone (GnRH) analogue<sup>6</sup> was used mainly for those patients with a myoma larger than 4 cm.

1. Myoma ≥5 cm in diameter. GnRH analogue depot-leuprolide acetate 1.88 mg (Lupron; Takeda Chemical Industries, Osaka, Japan) three doses (1 month/one injection) were prescribed.

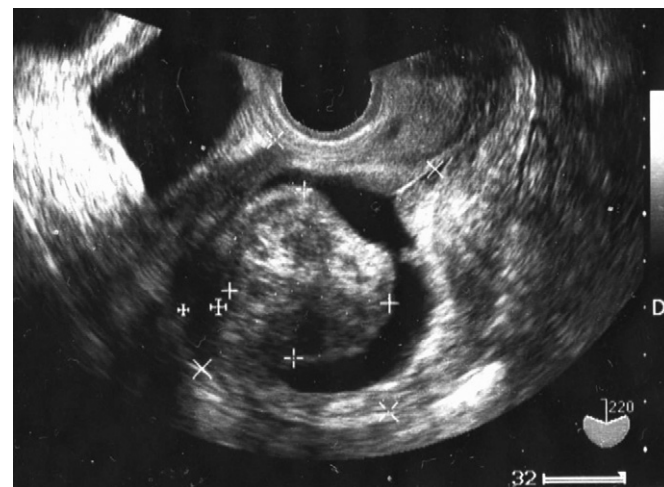

Fig. 2. Sonohysterography performed immediately after diagnostic hysteroscopy to measure the size of the submucous myoma (34.5 × 35.9 mm), serosa-myoma thickness (7.5 mm), and the uterus (65.4 × 62.6 mm).

2. 5 cm >myoma ≥4 cm in diameter. Two doses of GnRH analogue Lupron 1.88 were used.
3. No treatment for myoma <4 cm.

##### Cervical priming

A piece of laminaria tent (Nippon Laminaria Co., Gifu, Japan) was inserted into the uterine cavity the night before the surgery to soften and dilate the cervix.<sup>7</sup> If the insertion of laminaria tent was difficult, a piece of Lamicel (Medtronic Xomed, Inc., Jacksonville, FL, USA) was used instead.

Usually, laryngeal mask anesthesia was used. All procedures were monitored by concomitant abdominal ultrasonography.<sup>8</sup>

##### Instrumentation

The following instruments were used during the procedures: 22-French resectoscope (Kar Storz Co., Tuttlingen, Germany); Lin dissecting loop (Kar Storz Co.) (Fig. 4); Lin curved tenaculum (Atom Co., Tokyo, Japan); Lin myoma graspers (Fig. 5) used under ultrasound guidance; Lin self-retainer for holding the abdominal ultrasound probe.

##### Distending medium

The 3-L distending media (3% sorbitol solution; Baxter Co., Singapore, Japan) is delivered to the uterine cavity by simple gravity flow from approximately 100 cm above the patient. This process resulted in an intrauterine pressure of 72 mmHg as measured by the HP Component Monitoring System<sup>3</sup> (Agilent Technologies Co., Palo Alto, CA, USA). The fluid outflow was retrieved and the amount of deficiency was calculated.<sup>9</sup> Our limitation of fluid deficit was 1000 mL.

##### Techniques of resectoscopic myomectomy

- 1) Cutting the myoma pedicle (Figs. 6–9). We started using a 22-French resectoscope equipped with a Lin dissecting loop to cut into the cleavage between the myoma and the myometrium. After opening the space, the irrigating fluid flew into the cleavage, causing water dissection, and the space of the

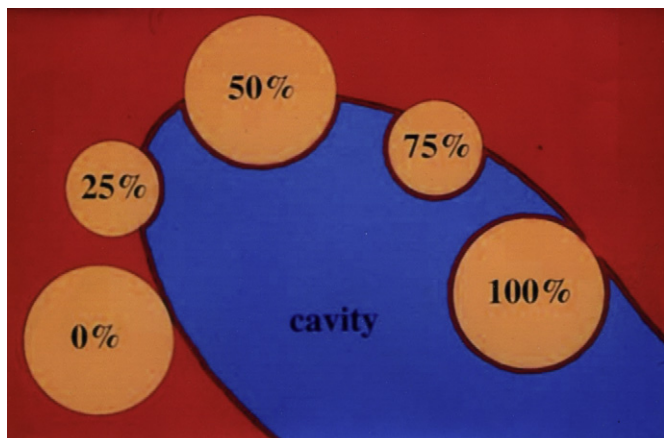
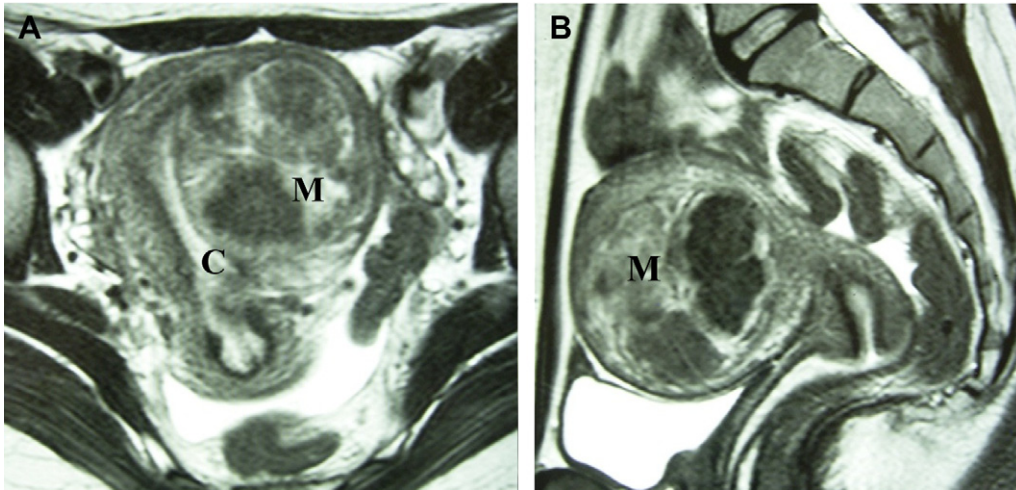


Fig. 1. Intrauterine protrusion of submucous myoma.



**Fig. 3.** Magnetic resonance imaging of a submucous myoma measuring approximately 61.7 × 57.0 × 57.3 mm with 10% intrauterine protrusion: (A) coronal view; (B) axial view. C = cavity; M = myoma.

cleavage was enlarged. The myoma was then dissected from the myometrium by cutting the tissue in the cleavage and pushing the myoma into the uterine cavity using a Lin dissecting loop. We followed the same principles of dissecting the myoma from the muscular layer as if the myomectomy was performed by scissors in an abdominal procedure. This procedure was done from both sides of the myoma to dissect and to move the myoma away from the myometrium to prevent potential uterine perforation.

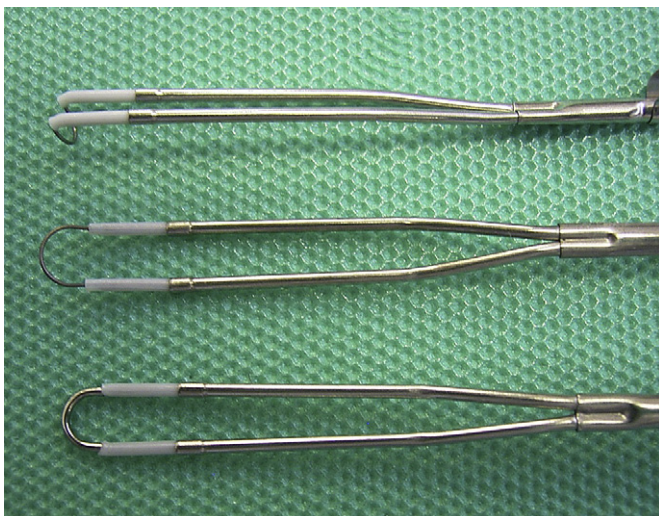
- 2) Cutting the myoma body (Figs. 10 and 11). The Lin dissecting loop was changed into a conventional cutting loop to shave the myoma from the dissected pedicle to create a space to allow a Lin myoma grasper (Atom Co.) to hold the myoma. The surface of the myoma was shaved into an uneven surface that enabled a grasper to hold the myoma firmly. Then the myoma was pulled farther into the intrauterine cavity. Extracting and rotating the myoma resulted in complete separation of the myoma from the muscular layer. Then, using a cutting loop, the myoma was cut and divided horizontally and vertically into quadrants by what we call a cross resection technique. The

myoma was torn and removed by the grasper. All the grasper procedures were done under ultrasound guidance.

#### Postoperative management

After the procedure, if continuous bleeding occurred, a 24- or 26-French balloon catheter (Norta, Beiersdorf, Germany) was introduced into the uterine cavity and the balloon was inflated with 10–15 mL normal saline to compress bleeding vessels. If the bleeding did not stop, the amount of balloon fluid was increased or the external cervical orifice was closed with an absorbable thread (Vicryl rapide; Johnson & Johnson Co., Tokyo, Japan). The intrauterine balloon and the cervical suture were removed on the first day after the surgery. A prophylactic oral antibiotic (Pansporin), 1000 mg, was given for 4 days.

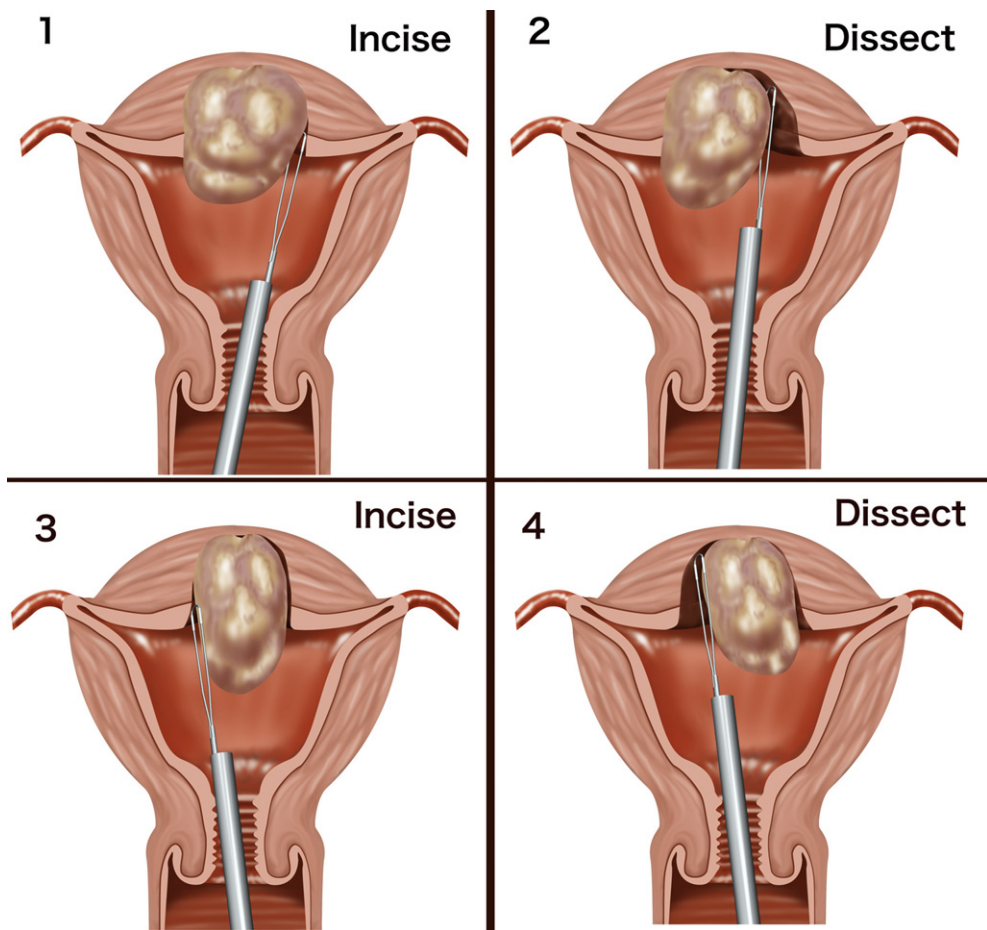
For those patients who desire to bear children, an intrauterine device (IUD) (FD-1; Fuji latex Co., Tochigi, Japan) was placed after the procedure to prevent intrauterine adhesions. Conjugated estrogen 1.875 mg/day for 10–14 days was given to those patients



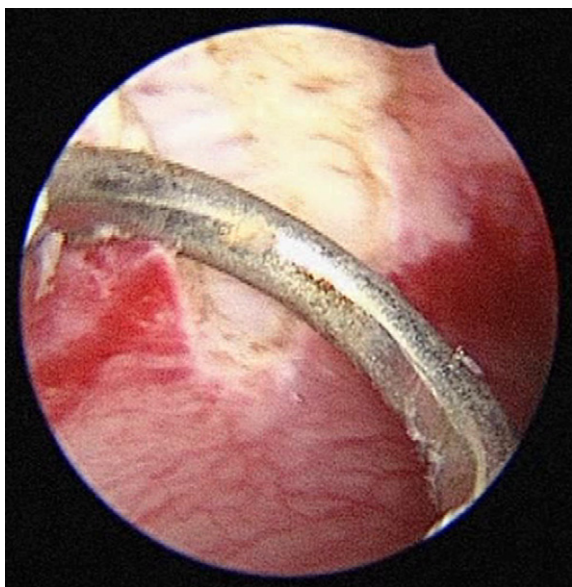**Fig. 4.** A conventional cutting loop, zero-degree cutting loop, and a Lin dissecting loop, seen from above.



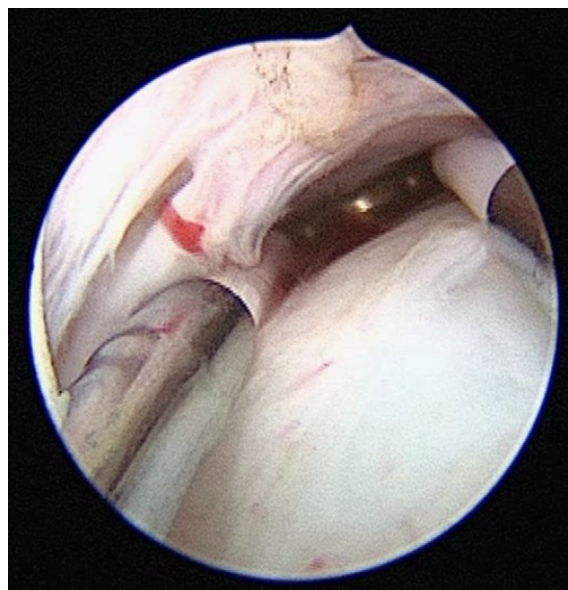
**Fig. 5.** A Lin myoma grasper.



**Fig. 6.** Steps of resectoscopic myomectomy. Cut from the left side to get into the plane of the cleavage between the myoma and the myometrium using the Lin dissecting loop. Dissect the myoma away from the myometrium. Then, the next step is to cut from the right side and dissect the myoma.



**Fig. 7.** The Lin loop is used to cut the junction between the myoma and the myometrium.



**Fig. 8.** A cut is made into the plane of the cleavage.

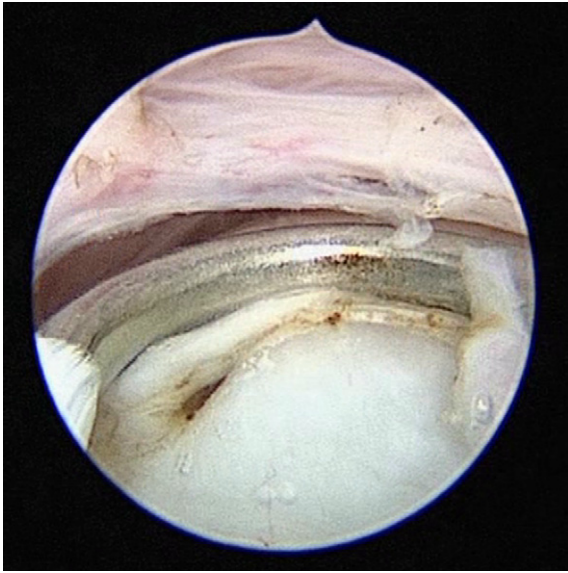

Fig. 9. The myoma is dissected away from the myometrium.

who used GnRH analogue therapy or with left large endometrial defect after resection. One month later, early second-look hysteroscopy was performed. If no abnormal finding was found, the IUD was removed. The patients were allowed to conceive 2 months

after the surgery. Vaginal delivery was the choice if there were no other indications for cesarean section.

All of the other patients returned for examination 1 month after the surgery. Because more than 90% of the patients were referred from other hospitals or local practitioners, we asked the patients to follow up with their own doctors. If any problem occurred, the patients will be sent back again for evaluation.

## Results

Of the 1569 patients, pedunculated submucous myoma, sessile submucous myoma, and intramural myoma were diagnosed in 943, 608, and 19 patients, respectively. The patient's median age was 38.6 years (range, 19–59 years). The surgical time was between 4 minutes and 147 minutes (mean  $30.6 \pm 18.2$  minutes). The specimen weighed from 0.1 g to 380 g (mean  $19.9 \pm 21.7$  g). The 380 g specimen was removed from a cervical myoma pretreated with selective arterial embolization. To prevent intrauterine adhesions, an IUD (FD-1) was placed in 1028 patients (65.5%). To stop bleeding, balloon compression was performed in 96 patients (6.1%) and balloon compression combined with closure of the external orifice in 20 patients (1.3%). Two cases of uterine perforation caused by the myoma grasper were encountered. Laparotomy was used to repair the wound. No hypernatremia was found. Almost all of the patients had improvement of symptoms. Long-term follow-up revealed five cases of abdominal total hysterectomy, one case of abdominal myomectomy, and 21 cases of rehysteroscopic operation. The pregnancy outcome was 60 cases of

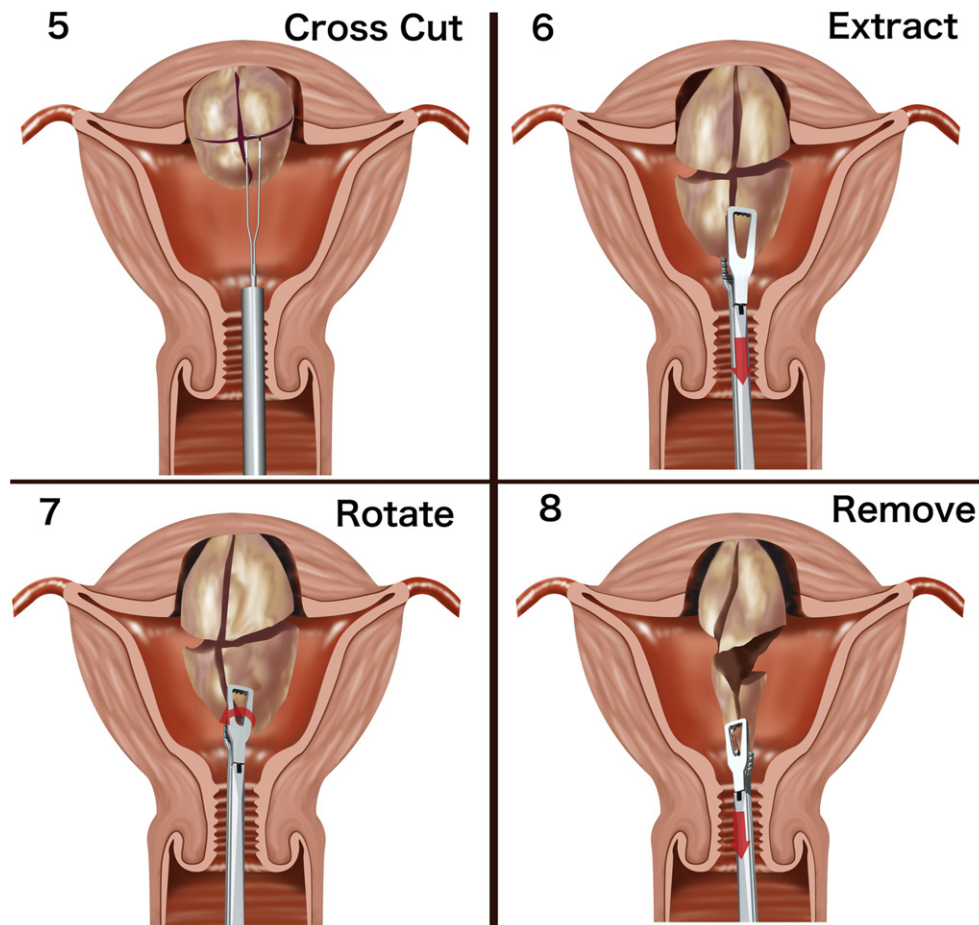


Fig. 10. Additional steps of resectoscopic myomectomy, continued from Fig. 6: Cut the myoma body to divide it into quadrants with a conventional cutting loop. Pull and extract the myoma with a Lin myoma grasper. Rotate the myoma to separate it from the muscle layer. Tear and remove the myoma.

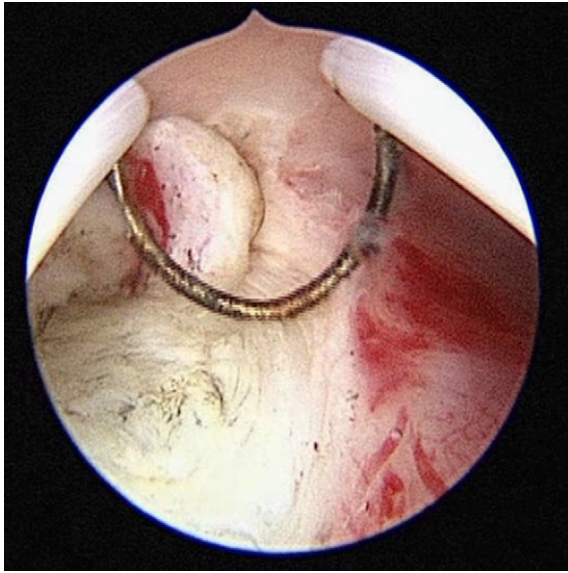


Fig. 11. A conventional cutting loop is used to shave the myoma body.

normal spontaneous delivery, 35 cases of cesarean section, five cases of ongoing pregnancy, and one case of spontaneous abortion. No case of uterine rupture was encountered. A case of placenta accreta that required hysterectomy was experienced.

Fig. 3 is an MRI of a 26-year-old woman, gravida 0 para 0. She underwent hysteroscopic myomectomy twice in our hospital, at ages 18 years and 24 years. During the first procedure, a pedunculated submucous myoma weighing 42 g was removed. During the second procedure, a pedunculated submucous myoma and 18 intramural myomas with a total weight of 20 g were removed. Two years after the second surgery, the patient returned with the chief complaint of heavy menstruation. The MRI showed a submucous myoma that measured approximately  $61.7 \times 57.0 \times 57.3$  mm with 10% intrauterine protrusion. After pretreatment with three doses of leuprolide acetate 1.88 mg, the patient underwent hysteroscopic myomectomy. A 90 g myoma was completely removed. The surgery time was 56 minutes. Eighteen months later, the patient conceived; a 2395 g infant was safely delivered by cesarean section at 36 weeks' gestation.

## Discussion

There are three factors that significantly determine the feasibility of hysteroscopic myomectomy: degree of myoma protrusion into the uterine cavity, and size and consistency of the myoma.<sup>10</sup>

The conventional technique of resectoscopic myomectomy is to use a resectoscope cutting loop to shave the myoma adjacent to the level of the endometrium. Usually dissection below the level of the endometrial cavity is prohibited because of the risk of hemorrhage, perforation, and fluid overload. In case of deeply invasive submucous myoma, two or more procedures are often required. Symptomatic intramural myoma, of course, is unable to be removed. Using our dissection technique, the myoma is dissected away from the myometrium first. Then the myoma is pulled, rotated, and torn using a Lin myoma forceps that enables complete removal in one procedure. Even a symptomatic intramural myoma, if the size is smaller or equal to 3 cm and the location can be navigated by the concomitant ultrasonography, can be removed completely with our technique.

Instead of European Society for Gynaecological Endoscopy (ESGE) classification of submucous myoma,<sup>11</sup> a widely used system, we use ratio classification, which describes the degree of the myoma protruding into the uterine cavity and the concept of SMT to predict the perioperative outcomes. With ESGE classification, perioperative outcome cannot be compared among patients of the same type. For example, there are two cases of submucous myoma with the same size and of the same type (3 cm in diameter and type II). One is a 40% intrauterine protrusion and the other is a 10% intrauterine protrusion. To compare the feasibility of surgery, it is obvious that the submucous myoma with 40% intrauterine protrusion is easier to remove. However, with ESGE classification no information can be obtained.

Our purposes for preoperative treatment with GnRH analogue are to decrease myoma volume, increase hemoglobin, and decrease blood loss during the operation. However, long-term treatment with GnRH analogue will cause loss of plane of cleavage and make myoma dissection more difficult. Therefore, we restrict the use of GnRH analogue to two or three doses and it is our belief that the dissection of myoma was less difficult.

Hysteroscopic myoma dissection is different from a laparoscopic or abdominal dissection. During a hysteroscopic dissection, there is another assisted power coming from water dissection, which is not used during the laparoscopic or abdominal approach.

To prevent cervical laceration that may be caused by the myoma grasper, cervical priming is very important, especially for nulliparous women who received GnRH analogue treatment. Several methods, including use of the laminaria tent, Lamicel, Dilapan, and Misoprostol, have been reported.<sup>12</sup> We had many opportunities to perform hysteroscopic myomectomy in other areas where the laminaria tent was not available. By comparison of different methods we conclude that the laminaria tent is the best method for cervical priming.

Starting in 1985, we have encountered more than 4000 cases of hysteroscopic myomectomy. All the procedures were done by the same surgeon. By comparison between the periods of using and without using Lin graspers (unpublished data), we conclude that there are three advantages of using myoma graspers: (1) Shortened surgical time. (2) Avoidance of fluid complications.<sup>13,14</sup> The surgical time to use the resectoscope is shortened. As a consequence, the amount of irrigating fluid can be reduced and the potential risk of fluid complications can be avoided. (3) Increased intracavitary protrusion of the myoma by means of grasping and extracting the myoma.

Use of coagulation current to stop uterine bleeding at the end of the procedure is the most popular method. However, profuse and extended bleeding may cause hyponatremia. A 24-French or 26-French balloon catheter can be used to compress the area of bleeding. Under ultrasound monitoring the balloon is inflated to the size of the preoperative submucous myoma. If the bleeding does not stop, the volume of balloon fluid is increased, which usually can stop the bleeding. If this step does not work or the bleeding comes from the vessels near the internal orifice, often a suture to close the external orifice can solve the problem. In case of prolapsed submucous myoma, the external cervical orifice is very wide and the balloon will easily slip into the vagina. Closure of the external cervical orifice is a good way to keep the balloon in the uterine cavity.

In case of vaginal bleeding with uterine perforation,<sup>15</sup> vasopressin injection is the most effective method to stop the bleeding. Using balloon compression, the balloon may be introduced through the perforated wound into the abdominal cavity.

Two cases of uterine perforation caused by myoma grasper were experienced. One was a nulliparous patient with a small and hard cervix; a laminaria tent could not be inserted before the surgery. The other perforation occurred because of attempts to remove a small

intramural myoma with a grasper after removal of a 105 g large myoma. No perforation was encountered during the dissection of the myoma.

To ensure the safety of the operation, a concomitant ultrasonography was used to monitor the entire procedure. However, an assistant was needed to hold the ultrasound probe. To solve this problem, we developed a Lin self-retainer that can be used to hold an abdominal ultrasound probe without an assistant.

## Conclusion

The advantages of our technique are to preserve more endometrium, lessen injury to the muscle layer, prevent fluid complications, and enhance a complete one-step removal of the myoma. Our results proved that our technique is a safe and efficient method for the treatment of submucous myoma.

## Conflicts of interest

The authors declare that they have no conflicts of interest.

## References

1. Valle RF. Development of hysteroscopy: from a dream to a reality, and its linkage to the present and future. *J Minim Invasive Gynecol*. 2007;14:407–418.
2. Indman PD. Hysteroscopic treatment of menorrhagia associated with uterine leiomyomas. *Obstet Gynecol*. 1993;81:716–720.
3. Lin BL, Akiba Y, Iwata Y. One-step hysteroscopic removal of sinking submucous myoma in two infertile patients. *Fertil Steril*. 2000;74:1035–1038.
4. Cheng YM, Lin BL. Modified sonohysterography immediately after hysteroscopy in the diagnosis of submucous myoma. *J Am Assoc Gynecol Laparosc*. 2002;9:24–28.
5. Yang JH, Lin BL. Changes in myometrial thickness during hysteroscopic resection of deeply invasive submucous myoma. *J Am Assoc Gynecol Laparosc*. 2001;8:501–505.
6. Campo S, Campo V, Gambadauro P. Short term and long term results of resectoscopic myomectomy with and without pretreatment with GnRH analogue in premenopausal women. *Acta Obstet Gynecol Scand*. 2005;84:756–760.
7. Lin BL, Iwata Y, Liu KH. Removing a large submucous fibroid hysteroscopically with the two-resectoscope method. *J Am Assoc Gynecol Laparosc*. 1994;1:259–263.
8. Lin BL, Iwata Y, Miyamoto N, Hayashi S. Three-contrasts method: an ultrasound technique for monitoring transcervical operations. *Am J Obstet Gynecol*. 1987;156:469–472.
9. Loffer FD, Bradley LD, Brill AI, Brooks PG, Cooper JM. Hysteroscopic training guidelines, from the Ad Hoc Committee on hysteroscopic training guidelines of the American Association of Gynecologic Laparoscopists. *J Am Assoc Gynecol Laparosc*. 2000;7:165.
10. Lin BL, Kasuga YF, Matsuoka TF, Higuchi TY, Nakada SK, Iwada SK. Unsuccessful hysteroscopic removal of a large calcified submucous myoma. *Jap J Obstet Gynecol Endosc*. 2010;26:422–424.
11. Wamsteker K, Emanuel MH, de Kruif JH. Transcervical hysteroscopic resection of submucous fibroids for abnormal uterine bleeding: results regarding the degree of intramural extension. *Obstet Gynecol*. 1933;82:736–740.
12. Lin YH, Hwang JL, Seow KM, Huang LW, Chen HJ, Hsieh BC. Laminaria tent vs misoprostol for cervical priming before hysteroscopy: randomized study. *J Minim Invasive Gynecol*. 2009;146:708–712.
13. Bradley L. Complications in hysteroscopy: prevention, treatment and legal risk. *Curr Opin Obstet Gynecol*. 2002;14:409–415.
14. Carter JE. Hysteroscopic surgery—avoid the complication of hyponatraemic encephalopathy. *Min Invas Ther Allied Technol*. 1997;6:241–248.
15. Loffer F. Complication of hysteroscopy: their cause, prevention, and correction. *J Am Assoc Gynecol Laparosc*. 1995;3:167–182.